

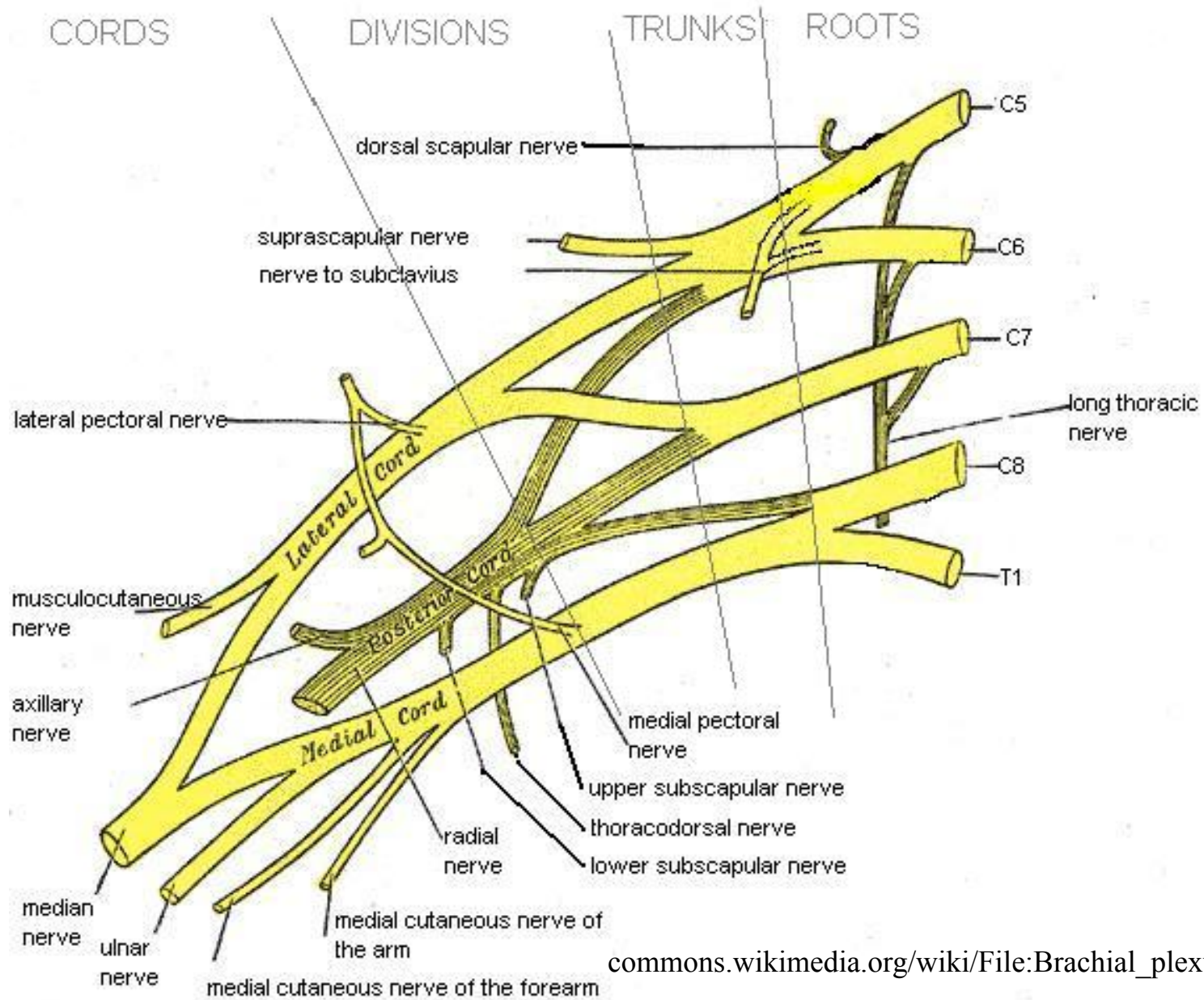


BRACHIAL PLEXUS INJURY INVESTIGATION , LOCALIZATION AND TREATMENT

EMBRYOLOGY

- Brachial plexus (BP) is developed at 5 weeks of gestation
- Afferent fibers develop from neuroblast located alongside neural tube
- Efferent fibers originate from neuroblast in the basal plate of tube from where they grow outside
- Afferent and efferent fibers join to form the nerve

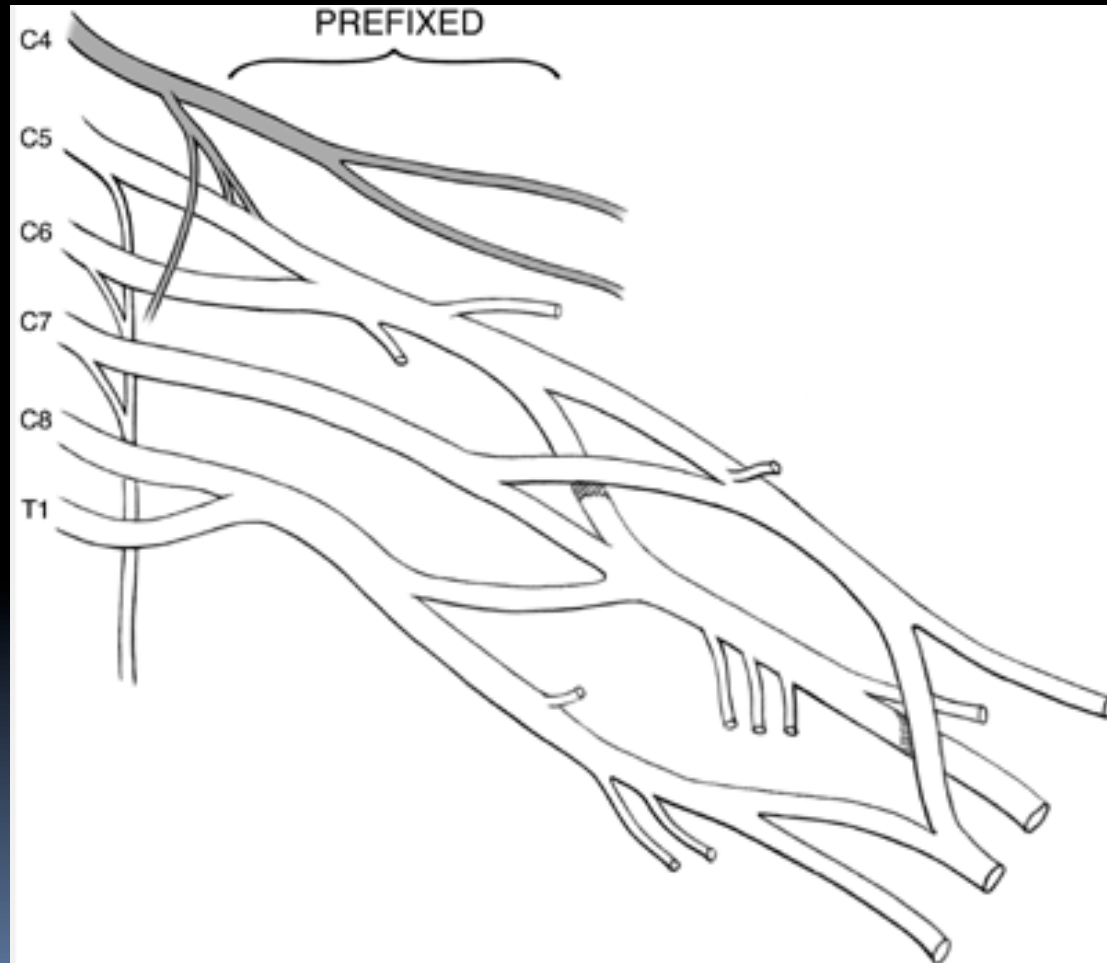- 
- 
- Nerves divide into anterior and posterior divisions
 - There are connections between these nerves in the brachial plexus



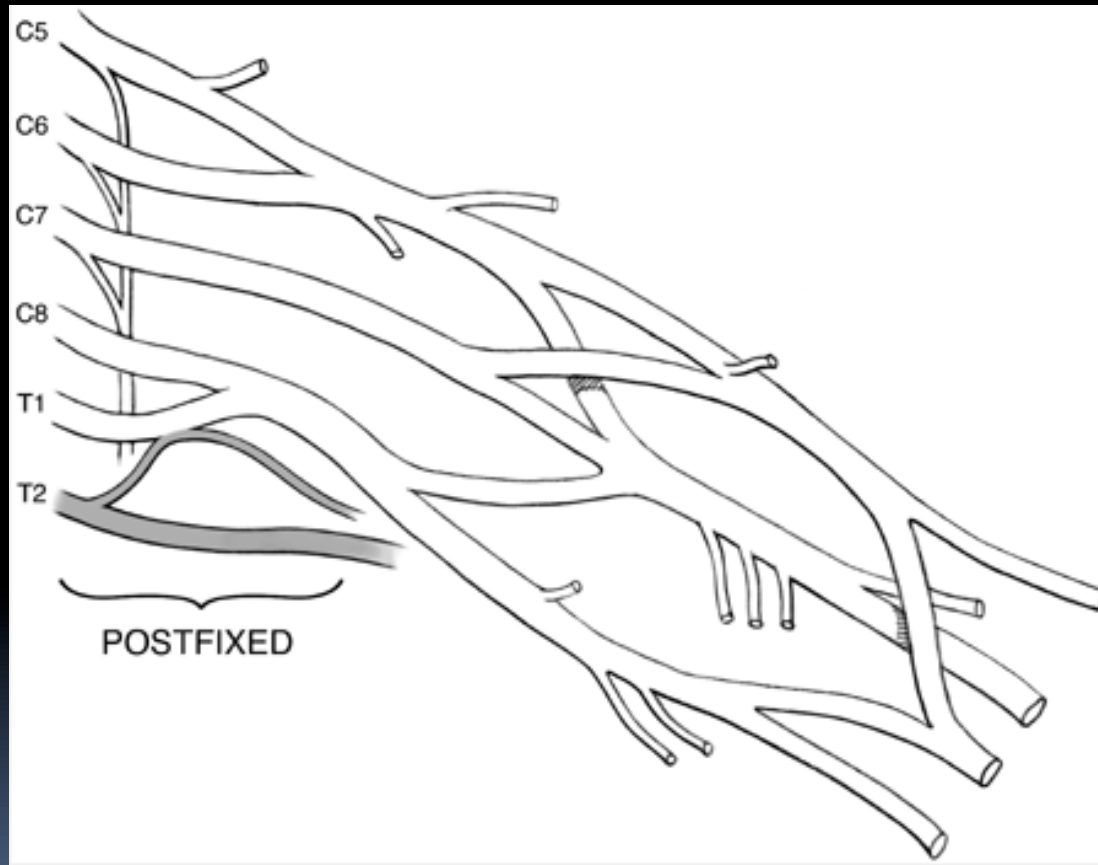
ANATOMY

- Formed by ventral primary rami of lower four cervical and first thoracic nerve root.
- Frequently have contributions from C₄(pre-fixed) or T₂(post-fixed).

PREFIXED BRACHIAL PLEXUS



Post-fixed plexus



RELATIONS OF BRACHIAL PLEXUS






Fig. 4. The relationship of the axillary artery to the cords is an important anatomic relationship. The cords surround the axillary artery and are named for their position with respect to the axillary artery. L.C. lateral cord MC. Medial cord: PC . posterior Cord.


Levels

- **R**oots
- **T**runks
- **D**ivisions
- **C**ords
- **B**ranches
- **R**eal
- **T**exans
- **D**rink
- **C**old
- **B**eer

- 
- C₅ and C₆ roots form upper trunk
 - C₈ and T₁ roots the lower trunk
 - C₇ forms the middle trunk
 - Joining point of C₅-C₆ roots is *ERB'S POINT*
 - Each trunk divides into an anterior and a posterior division and passes beneath the clavicle

- 
- All 3 posterior divisions merge to form the posterior cord
 - Anterior division of the upper and middle trunk merge to form the lateral cord
 - Anterior division of lower trunk forms the medial cord


- Lateral cord splits into 2 terminal branches:
 - a) Musculocutaneous nerve
 - b) Lateral cord contribution to median nerve (sensory)
- Posterior cord splits into
 - a) axillary nerve and
 - b) radial nerve
- Medial cord gives off
 - a) medial cord contribution to the median nerve (motor) and
 - b) ulnar nerve

- 
- There are few terminal branches of the roots trunks and cords.
 - ROOTS: a) dorsal scapular nerve b) branch to phrenic nerve c) Long thoracic nerve
 - TRUNKS: a) nerve to subclavius b) suprascapular nerve
 - CORDS: a) Lateral cord gives lateral pectoral nerve b) Posterior cord gives upper subscapular, lower subscapular and thoracodorsal nerve.

- 
- Medial cord gives medial pectoral, medial cut. nerve of arm and forearm.





Variations

- Found in around 50%
 - Most commonly pre-fixed(28-62%) and post-fixed(16-73%)
- 



Patho-anatomy

- Anatomy of rootlets, roots and vertebral foramen contribute to the type of injury
- Rootlets forming the cervical roots are intraspinal and lack connective tissue or meningeal envelope.
- This feature makes them vulnerable to traction and susceptibility to avulsion at the level of cord.
- The spinal nerve is able to move freely in the foramina due to non attachment to it.

- 
- 
- There is fibrous attachment of spinal nerves to the transverse process seen in the 4th through 7th cervical roots
 - This explains the high incidence of root avulsions in C8-T₁ roots

- Preganglionic

Tearing of rootlets
proximal to dorsal
root ganglia

a) central

b) peripheral


- Postganglionic



Injury distal to DRG



Pathogenesis

- Most patients are men and boys between 15-25 years
- 70% of traumatic BPI secondary to motor vehicle accidents
- Of these 70% involve motorcycles and bicycles
- Other major injuries usually associated in 70%

- 
- They are usually closed injuries
 - 95% traction injuries, 5% compression injuries
 - Supraclavicular more common than infraclavicular involvement
 - Roots and trunks most commonly involved
 - Root avulsions: 2 mechanisms
 - peripheral- common
 - central- rare

- 
- Traction injuries head and neck move away from shoulder, usually involve C₅, C₆ and C₇
 - C₈- T₁ involved in hyperabduction injuries
 - Other mechanisms- penetrating injuries
iatrogenic injuries
- 


MECHANISM OF INJURY

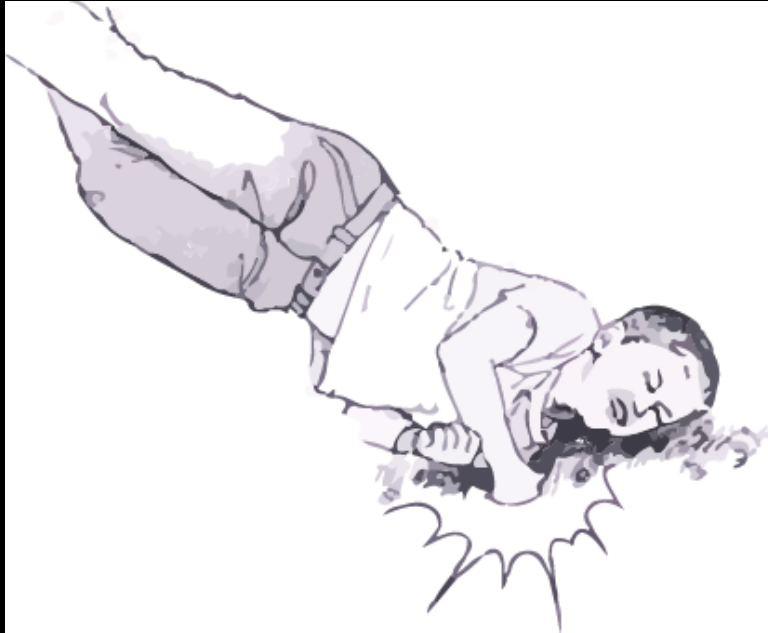


Fig. 6. Upper brachial plexus injuries occur when the head and neck are violently moved away from the ipsilateral shoulder. The shoulder is forced downward whereas the head is forced to the opposite side. The result is a stretch, avulsion, or rupture of the upper roots (C5, C6, C7), with preservation of the lower roots (C8, T1)

Clinical features

- High degree of suspicion in injury to shoulder girdle, first rib and axillary artery
- Median, ulnar and radial nerves can be evaluated by examining finger and wrist motion
- Elbow flexion and extension can be used to examine musculocutaneous nerve and high radial nerve function
- Injury to posterior cord may affect deltoid function and muscles innervated by radial nerves

- 
- Latissimus dorsi innervated by thoracodorsal nerve is palpated posterior axillary fold
 - Medial and lateral pectoral nerves are branches of medial and lateral cord respectively and supply sternal and clavicular head of pectoralis major respectively
 - Supra scapular nerve function shoulder extension, rotation and elevation
 - Look for Horner syndrome, injury to long thoracic nerve and dorsal scapular nerve to differentiate between pre and post ganglionic lesion

- 
- Assess spinal accessory nerve
 - Active passive range of motion
 - Rule out cord injury
 - Tinel's sign
 - Vascular examination
 - Fractures

PREOPERATIVE PLANNING

Box 1. Preoperative planning priorities for brachial plexus injury surgery


1. Review clinical examinations
2. Scrutinize electrodiagnostic studies
3. Review CT myelography/imaging
4. Assemble operative team, plan for intraoperative electrodiagnostic studies
5. Plan a preoperative conference, including priorities and contingency plans
6. Prepare patient's expectations

IMAGING

- Radiography- cervical spine views
 - shoulder view- AP and axillary
 - X- Ray chest
- CT myelography- gold standard for root injury, done at 3 to 4 weeks to see for pseudo meningocele formation
- MRI shows whole of brachial plexus, cord injury and neuroma formation



ELECTRODIAGNOSTIC STUDIES

- Can help confirm a diagnosis
 - Localize lesions
 - Define severity of axon loss and completeness of lesion
 - Serve as an important adjunct to thorough history, physical exam and imaging study
- 

- 
- For closed injuries EMG and NCV can best be performed 3 to 4 weeks after the injury because wallerian degeneration will occur by this time



EMG

- Denervation changes(fibrillation potentials) can be seen in proximal muscles 10 to 14 days and 3to6 weeks post injury in most distal muscles
- Reduced MUP(motor unit potential) recruitment can be shown immediately after weakness from LMN injury
- Presence of active motor units with voluntary effort and few fibrillations at rest has good prognosis
- Can help in distinguishing preganglionic from postganglionic lesions




NCS

- In post traumatic BPI the amplitude of compound muscle action potentials (CMAP) are generally low
- SNAP important in localizing a lesion as pre or postganglionic



INTRA OP TESTING

- NAP (nerve action potential)
 - SEP (somatosensory evoked potential)
 - CMAP (compound muscle action potential)
- 

Management

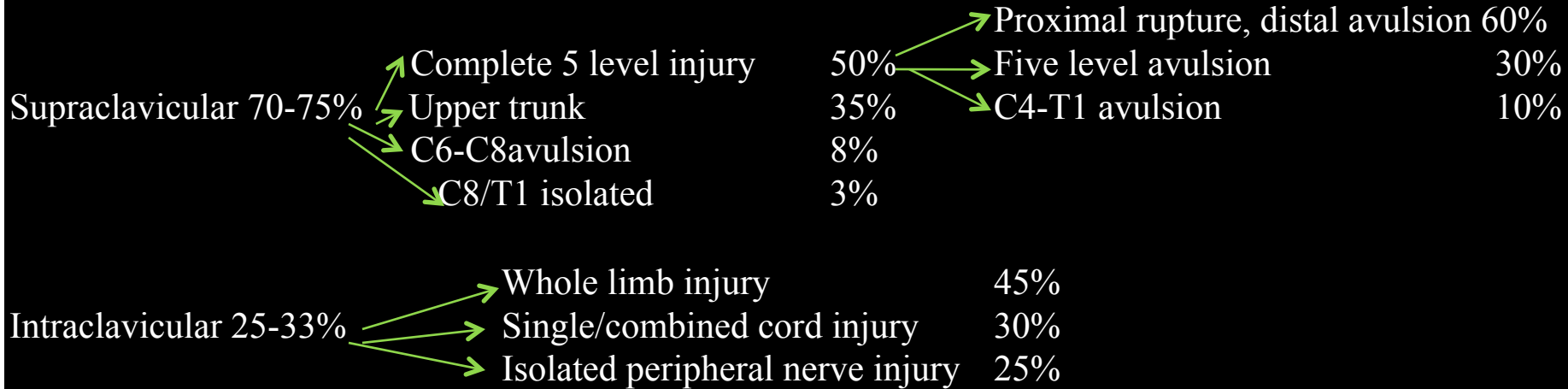




Fig. I. Distribution of location and iv of hrachical plesus injuries.



Management

- 15% of supraclavicular injuries have concomitant segmental injuries at or below the clavicle where the peripheral nerve branch from the plexus
 - Musculocutaneous, axillary and suprascapular nerves are particularly vulnerable to traction injury because of soft tissue tethering near their origin
- 

- 
- Infraclavicular injuries constitute 25- 33% of BPI usually occur at cords or peripheral nerves and usually are incomplete
 - Usually caused by shoulder fracture or dislocation
 - 5- 25% of infraclavicular injuries are associated with axillary artery injury
 - Penetrating injuries are usually infraclavicular

Timing of intervention


- A - acute exploration
concomitant vascular injury
open injury by sharp laceration
crush or contaminated wound
- B - early exploration (1- 2 weeks)
unequivocal complete C5- T1 avulsion injuries
- C - delayed exploration > 3 months
recommended for complete injuries with no recovery by
clinical examination or EMG at 12 weeks post injury
candidates showing distal recovery without regaining
clinical or electrical evidence of proximal muscle function

Prioritization

- Clearly understand the anatomy of injured plexus
- What is available for nerve transfer
- Function priority- elbow flexion is the most important to restore followed by abduction, external rotation and scapular stabilization
- Long thoracic nerve should be performed whenever possible
- Radial nerve motor function can often be restored with triceps function more likely to return




Surgical options

- Neurolysis
 - Nerve repair
 - Nerve graft
 - Nerve transfer or neurotization
 - Functional free muscle transfer
- 



Neurolysis

- Effective only if scar tissue seen around nerve or inside epineurium, preventing recovery or causing pain
 - Pre and post neurolysis direct nerve stimulation is mandatory to evaluate improvement in nerve conduction
- 



Nerve repair


- Used in sharp transection with excellent fascicular pattern and minimal scar
- 

Nerve graft



- Indicated for well defined nerve ends without segmental injuries
- Intraoperatively a good fascicular pattern should be seen after the neuroma is excised
- Possible sources: sural, brachial cutaneous nerve, radial sensory and possibly ulnar nerve
- Before implantation graft orientation should be reversed to minimize axonal branch loss
- Surgical technique is considered the most important factor in nerve graft

Neurotization

- A- intraplexal
- B- extraplexal
- Plexoplexal options are undamaged roots
- Other options include medial pectoral nerves and medial cord ulnar nerve
- Extraplexal options- spinal accessory, intercostal, phrenic and motor branch of deep cervical plexus



For upper arm type avulsion, a reliable neurotization strategy has included phrenic-suprascapular nerve transfer and spinal accessory nerve (with an interpositional nerve graft) to musculocutaneous nerve.



For complete avulsion injury, a strategy of multiple neurotizations using spinal accessory, phrenic and contralateral C7 nerves provides a patient with a framework to obtain hook grip.

- OBERLIN TECHNIQUE


- For upper trunk injury with intact lower trunk- 1 to 2 fascicles of ulnar nerve are anastomosed to biceps
- Contra lateral C7 is used in pan brachial plexopathy with multiple avulsions and limited donor possibility
- Contra lateral C7 root can be extended by means of vascularised ulnar nerve graft in patient with C8 T1 avulsion and median nerve is the most frequent recipient
- Another option is transferring nerve to long head of triceps to anterior branch of axillary nerve

Realistic targets to reinnervation

- Spinal accessory to suprascapular or musculocutaneous
- Phrenic to axillary nerve
- Intercostal to musculocutaneous long thoracic, radial and median nerve
- Long head of triceps nerve to anterior branch of axillary nerve



Functioning free muscle transfer


- Usually gracilis is used- single or double gracilis transfer
- 

PROGNOSIS

- Highly dependent on pattern of injury
- Complete C₄ to T₁ injuries are considered most severe and virtually irreparable
- Avulsion injuries from C₅ to T₁ amenable to restoration of shoulder and elbow function only
- Ideal candidate for surgery are patients with proximal rupture or avulsion and sparing of lower trunk

AIIMS STUDY

- Since 1995 to 2002 , 505 patients were studied for functional and occupational outcome after surgery for BPI
- In India BPI is most common due to RTA with Rt side involved in 2/3
- 40% cases have pan BPI
- 85% of cable graft yielded improvement in motor power compared 68% in neurotized nerve and 66% in patients undergoing neurolysis

- 
- Most effective donor nerve for musculocutaneous neurotization was medial pectoral nerve (63.6%) patient improved
 - Accessory nerve was most effective for neurotization of suprascapular nerve (100%)
 - Thoracodorsal axillary neurotization gave (66.7% improvement)
 - 50% patients either remained unemployed or had to change their jobs



Thank you