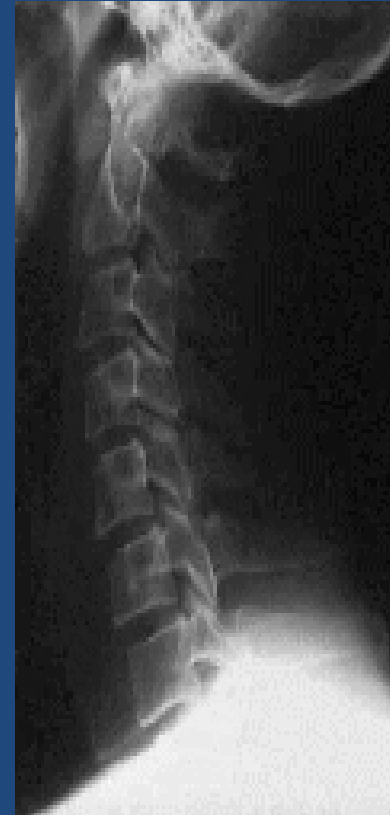

# **SUBAXIAL CERVICAL SPINE TRAUMA- DIAGNOSIS AND MANAGEMENT**

# Anatomy

- 3 columns- Anterior, middle and Posterior
- **Anterior**- ALL, Anterior 2/3 rd body & disc.
- **Middle**- Posterior 1/3<sup>rd</sup> of body & disc, PLL
- **Posterior**- Pedicle, lamina, facet, transverse process, spinous process, Ligaments- interspinous, lig.flavum
- **Articulations**- Disc-vertebral body, Uncovertebral , Zygapophyseal joints.



# Cervical spine injuries

- Common cause of disability
- Incidence
  - Spine without cord injury- 3%
  - Cord without #- 0.7%
- Most commonly involves C5 and C6 levels.
- Primarily involves adolescents and young adults
- Males predominate.
- Most common causes-
  - RTA, Fall, Penetrating trauma, Sports

# Clinical features

- Neck pain
- Restriction of neck movements
- Neck tenderness
- Varying degrees of neurological deficits
  - Complete cord syndrome
  - Incomplete cord syndrome
    - Central cord syndrome
    - Brown-Sequard syndrome
    - Anterior cord syndrome
    - Combination

# Mechanisms of injury

A-Axial compression force

B- Hyperextension injury

C- Hyperflexion injury

# By mechanisms of injury

- Flexion
  - Anterior subluxation
  - Unilateral facet dislocation
  - Bilateral facet dislocation
  - Wedge compression fracture
  - Flexion teardrop fracture
  - Clay Shoveler's fracture
- Extension
  - Hangman's fracture
- Compression
  - Jefferson fracture
  - Burst fracture
- Complex
  - Odontoid

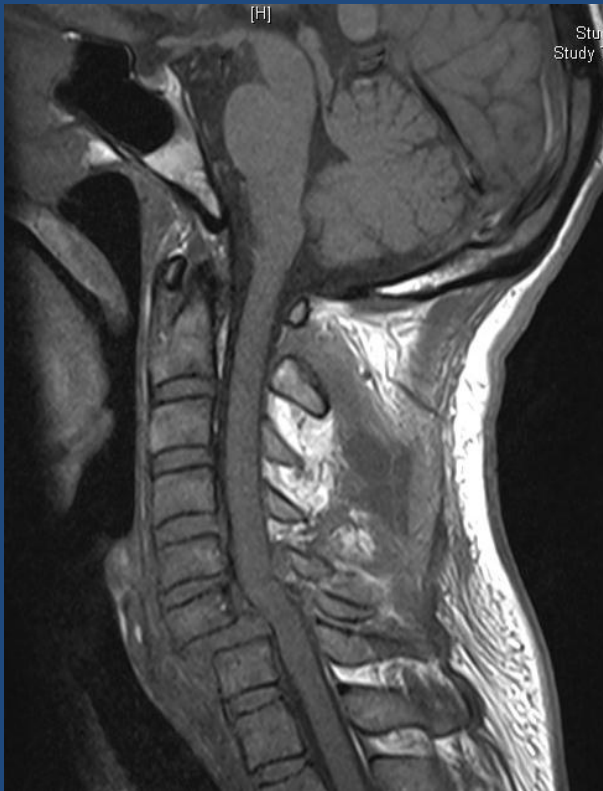- IMAGING
- Lateral view
  - Disc spaces, vertebral body, facet joints
- AP view- Spinous process, Uncovertebral joints
- Oblique view- Foramina, pedicles, facet joints, lateral mass, lamina

- Up to 20 % of fractures are missed on conventional radiographs.
- The sensitivity and specificity of CSR to detect fractures around 31.6 and 99.2%, respectively.
- For radiographic clearance of the cervical spine- CT is a must.
- CT- Excellent details about the # morphology.



# MR Imaging

- Excellent soft tissue detail
- To detect
  - spinal cord integrity/ spinal cord changes/ disc herniations/ epidural blood
- Supplementary to CT spine.



# Classification

- AO SPINE
- SLIC
- Allen

# AO spine classification

- Based on 2 column concept of Nicolle and Holdsworth.
- Similar to the ones of thoraco-lumbar injuries
- 3 types- based on fundamental injury patterns
  - A- vertebral body compression
  - B- anterior and posterior element with distraction
  - C- anterior and posterior element with rotation
- Each type has 3 groups with 3 sub groups
- Isolated spinous/ transverse process # not considered.
- Type B and type C injuries are the dominating cervical spinal injuries.
- The severity in terms of instability of the injuries as well as the rate of neurological deficits does not continuously increase from A to C in the cervical spine as it does in the thoracolumbar spine.

# Type A (Compression) Fractures

- Axial compression with or without flexion.
- Height of vertebral body (anterior column) reduced.
- Shortening of the anterior column
- Posterior ligamentous complex intact (flexion/extension x-rays, MRI).
- Translation in sagittal plane does not occur.
- Rare in comparison to the thoracic and lumbar spine.
- Posterior elements' disruption to be always ruled out so as to classify as type A injury.

# Group A1- Impaction #

- Deformation of the vertebral body is due to compression of the cancellous bone rather than to fragmentation.
- Posterior column is intact.
- Narrowing of the spinal canal does not occur.
- Injuries are stable.
- Posterior vertebral body wall is intact.
- Neurological deficit is very rare

A1.1 end-plate impaction

A1.2- wedge impaction

- Superior wedge impaction
- Lateral wedge impaction
- Inferior wedge impaction

A1.3-Vertebral collapse fracture.

- Rare in cervical spine.
- No subluxation.
- Posterior elements remain intact.

# Group A2- split #

- Vertebral body is split in the coronal or sagittal plane with a variable degree of dislocation of the main fragments.
- When the main fragments are significantly dislocated, the gap is filled with disc material which may result in a nonunion .
- Neurological deficit is uncommon
- The posterior column is not affected.

A2.1- Sagital split #

A2.2- Coronal split#

A2.3- Pincer #

- Pincer #- Coronal fracture with dislocation of main fragments



# Group A3- Burst #

- Vertebral body is partially or completely comminuted with a centrifugal extrusion of fragments.
- Fragments of the posterior wall are retropulsed into the spinal canal and may be the cause of neural injury.
- The posterior ligamentous complex is intact.
- Injury to the arch, if present, is always a vertical split through the lamina or spinous process.

- A3.1 incomplete burst fracture
  - 1. superior incomplete burst fracture
  - 2. lateral incomplete burst fracture
  - 3. inferior incomplete burst fracture
- A3.2 burst-split fracture
  - 1. superior burst-split fracture
  - 2. lateral burst-split fracture
  - 3. inferior burst-split fracture
- A3.3 complete burst fracture
  - 1. pincer burst fracture
  - 2. complete flexion burst fracture
  - 3. complete axial burst fracture
- Pathognomonic feature-
  - Broken, shortened posterior wall and
  - Subsequent narrowing of the spinal canal often combined with a neurological deficit.
  - Disc also usually involved.

# TYPE B INJURIES—ANTERIOR AND POSTERIOR ELEMENT INJURY WITH DISTRACTION

- Account for almost half of all injuries
- B component of an injury has to be looked carefully because it changes the prognosis dramatically
- Typical features:
  - **Transverse** disruption of one or both spinal columns initiated by flexion-distraction (posterior) or hyperextension (anterior).
  - Translation dislocation in the **sagittal direction**.
- The main criterion is a transverse disruption of one or both spinal columns.
- Flexion/distraction initiates posterior disruption and elongation (B1 and B2)
- Hyperextension with or without anteroposterior shear causes anterior disruption and elongation (B3).
- In B1 and B2 injuries, the anterior lesion may be through the disc or a type A fracture of the vertebral body.

## Group B1- Posterior disruption primarily ligamentous (Flexion distraction injuries)

- Leading feature is disruption of the posterior ligamentous complex with bilateral subluxation, dislocation, or facet fracture.
- Pure flexion-subluxations are only unstable in flexion, whereas pure dislocations are unstable in flexion and shear.
- Neurological deficit is frequent and caused by translational displacement and/or vertebral body fragments retropulsed into the spinal canal.

- B1.1- With transverse disruption of the disc
  - 1. Flexion subluxation
  - 2. Anterior dislocation
  - 3. Flexion subluxation/ anterior dislocation with # of articular process
- B1.2- With type A # of vertebral body
  - 1. Flexion subluxation with type A # of body
  - 2. Anterior dislocation with type A # of body
  - 3. Flexion subluxation/ anterior dislocation with # articular process and type A # of body

## Group B2- Posterior disruption primarily osseous (flexion-distraction injuries)

- B2.1 transverse bi-column fracture (channel fracture)
- B2.2 with disruption of the disc
  - .1 disruption through the pedicle and disc
  - .2 disruption through the pars interarticularis and disc (flexion spondylolysis)
- B2.3 with type A fracture of the vertebral body
  - .1 fracture through the pedicle and type A fracture
  - .2 fracture through the pars interarticularis (flexion spondylolysis) and type A fracture

## Group B3-anterior disruption through the disc (hypertension-shear injuries)

- B3.1 hyperextension-subluxation
  - .1 without injury of the posterior column
  - .2 with injury of the posterior column
- B3.2 hyperextension spondylolysis
- B3.3 posterior dislocation

## Type C- Anterior and posterior element injury with rotation

- Rotational displacement.
- Translational displacement in the coronal plane (pathognomonic).
- Unilateral fractures of articular and transverse processes.
- Lateral avulsion fractures of the end plate.
- Account for 40% of all injuries in the lower cervical spine.
- Therefore have a significant clinical importance.



# Group C1: type A (compression) injuries with rotation

- Very rare injuries.
- C1.1 rotational wedge fracture
- C1.2 rotational split fracture
  - .1 rotational sagittal split fracture
  - .2 rotational coronal split fracture
  - .3 rotational pincer split fracture
- C1.3 vertebral body separation (rotational burst fracture)
  - .1 incomplete rotational burst fracture
  - .2 rotational burst-split fracture
  - .3 complete rotational burst fracture

## Group C2: Type B injuries with rotation

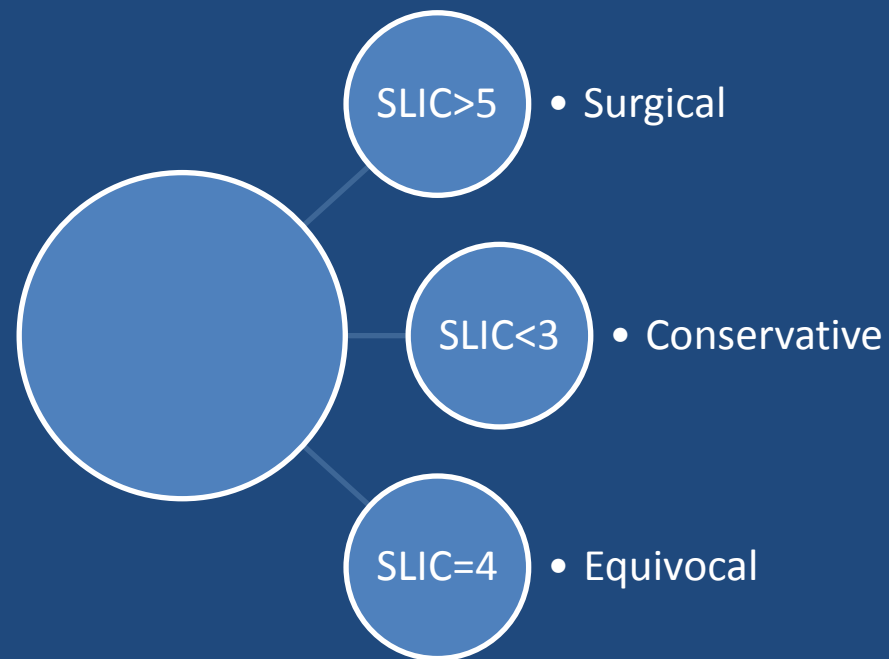
- C2.1- B1 injury with rotation (flexion-distraction injury with rotation)
- C2.2- B2 injury with rotation (flexion-distraction injury with rotation)
- C2.3- B3 injury with rotation (hyperextension-shear injury with rotation)
- Flexion-rotation dislocation, unilateral facet interlocking, or dislocation are other commonly used terms for these—in most cases relatively stable—injuries.
- Radiologic signs:
  - 3–4 mm subluxation of the vertebral body
  - Abrupt change in the width of the interlaminar space.
  - Alignment of the spinous processes may be impaired.

## Group C3- Rotation shear injuries

- Most unstable injuries.
- C3.1 slice fracture
- C3.2 oblique fracture
- C3.3 Complete separation

- **Table 1. Subaxial Injury Classification (SLIC) Scale**

	Points
<b>Morphology</b>	
• No abnormality	0
• Compression, burst	1, + 1 = 2
• Distraction ( <i>e.g., facet perch, hyperextension</i> )	3
• Rotation or translation ( <i>e.g., facet dislocation, unstable teardrop or advanced stage flexion compression injury</i> )	4
<b>Discoligamentous complex</b>	
• Intact	0
• Indeterminate ( <i>e.g., isolated interspinous widening, MRI signal change only</i> )	1
• Disrupted ( <i>e.g., widening of anterior disk space, facet perch or dislocation</i> )	2
<b>Neurological status</b>	
• Intact	0
• Root injury	1
• Complete cord injury	2
• Incomplete cord injury	3
• Continuous cord compression (neuro modifier in the setting of a neurologic deficit)	+1



# Which ones to be operated?

Type A 2 injuries

Type A 3 injuries

Type B injuries

Type C injuries

# Management

- Assess ABC
- Initial neck immobilization in a hard collar.
- Assess neurological status.
- Check for associated injuries.
- Role of steroids- Not a guideline (Only Class III evidence)
- Imaging- Digital X ray C-spine, NCCT spine+/- MRI
- Conservative v/s surgical management

# Goals of treatment

- A pain free patient with normal spinal function and a clinically stable spine
- The maintenance or recovery of neurological function by reduction and decompression of neural elements.
- Restoration of a physiological spinal alignment.
- A definite bony healing of a surgically fused spinal segment.
- An as short as possible stabilization and fusion
- Number of segments involved in surgical management to be kept to a minimum.

# Conservative treatment

- Can be done in less severe deficits (ASIA D,E)
- Cervical traction
- Early mobilization (to prevent chest infections and bedsores)
- Physiotherapy (Limb and chest)



# SURGICAL TREATMENT

- Timing of surgery
- Type of surgery ( Anterior/ Posterior/ Combined)

# Timing of surgical intervention

- No clear consensus yet.
- Currently no standards regarding the role and timing of decompression in acute SCI.
- For injuries of the cervical spine there is some evidence that neurological recovery improved when the dislocation was reduced as early as possible
  - Indication, surgical technique and surgical results of 100 surgically treated # and #-dislocations of cervical spine. *Clin Orthop Relat Res; (203):244–257.*
- Currently no standards regarding the role and timing of decompression in acute SCI.
- Role of surgical decompression in patients with SCI is only supported by Class III and limited Class II evidence.
  - *J Neurosurg.* 1999 Jul;91(1 Suppl):1-11.

- Early treatment in acute central cord injuries
  - Reasonable and safe to consider early surgical decompression (<24 hrs) in patients with profound neurologic deficit (ASIA = C) and persistent spinal cord compression due to developmental cervical spinal canal stenosis without fracture or instability.
    - Spine (Phila Pa 1976). 2010 Oct 1;35(21 Suppl):S180-6.
  - Surgical intervention consisting of Open door expansile cervical laminoplasty can be safely applied in the subset of patients with ATCCS without instability who have significant cervical spondylosis/stenosis. 29 cases. Average delay from injury to surgery was 3 days.
    - Surg Neurol. 2005 Jun;63(6):505-10
  - Surgical decompression, however, was associated with immediate neurologic improvement, faster recovery of neurologic function, early mobilization, better long-term neurologic outcome, briefer hospital stays, and fewer complications related to long confinements in bed than was nonoperative treatment. 13/16 showed improvement.
    - Spine (Phila Pa 1976). 1998 Nov 15;23(22):2398-403.

- Recommended- Urgent decompression of bilateral locked facets in a patient with incomplete tetraplegia or in a patient with SCI with neurologic deterioration. Urgent decompression in acute cervical SCI remains a reasonable practice option and can be performed safely. There is emerging evidence that surgery within 24 hours may reduce length of intensive care unit stay and reduce post-injury medical complications.
- 66 articles were reviewed including 1 RCT
  - Spine (Phila Pa 1976). 2006 May 15;31(11 Suppl):S28-35.

# Anterior approaches

- Discectomy and fusion.
- Corpectomy
- Anterior cervical plating

# Posterior approaches

- Posterior wiring technique and bone grafting approach
  - Injuries of the posterior complex involving predominantly soft tissue with insignificant damage to the vertebral body.
  - Enhancement of other posterior fusion techniques.
- Lateral mass fixation
  - Posterior stabilization of the cervical spine from C3 to C7.
  - Biomechanically stronger than posterior wiring techniques and anterior plating
  - Risks of injury to the vertebral artery and segmental nerve.
- Others- not generally performed nowadays
  - Interlaminar clamps
  - Sublaminar wiring