

CEREBROSPINAL FLUID RHINORRHOEA & ITS MANAGEMENT

Presented by : Dr Sachin A Borkar

**Department of Neurosurgery,
AIIMS, New Delhi**

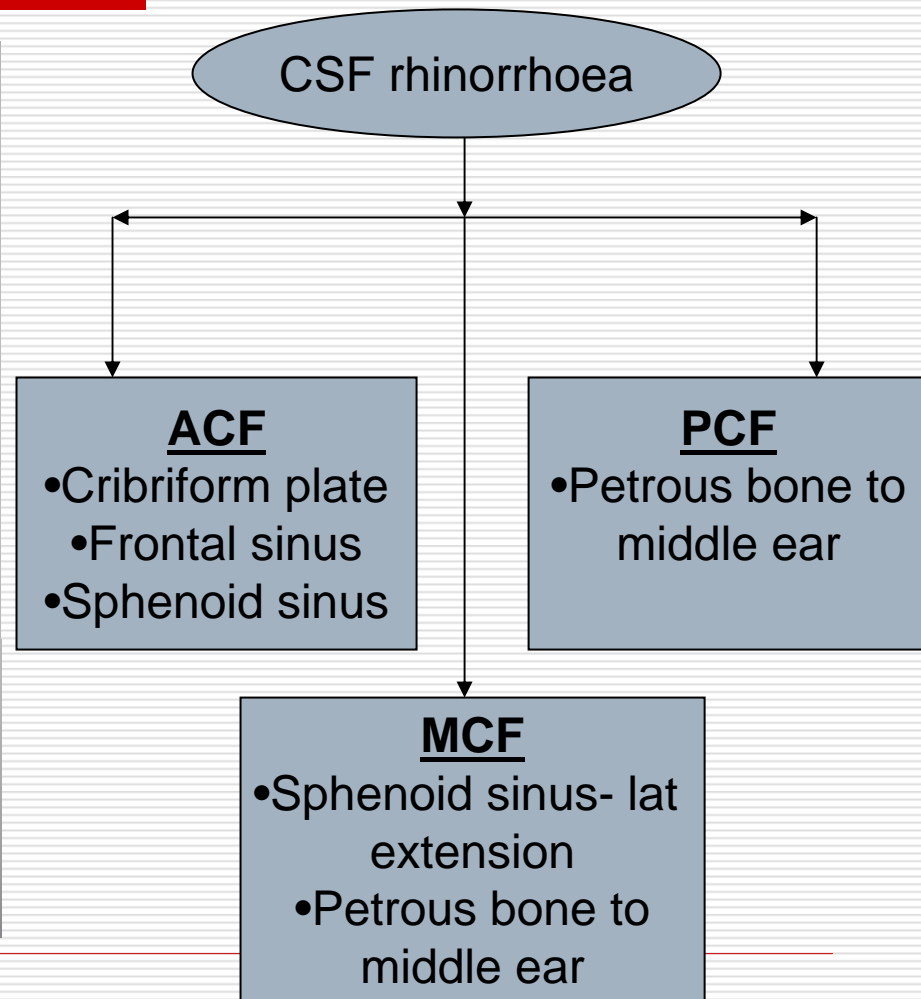
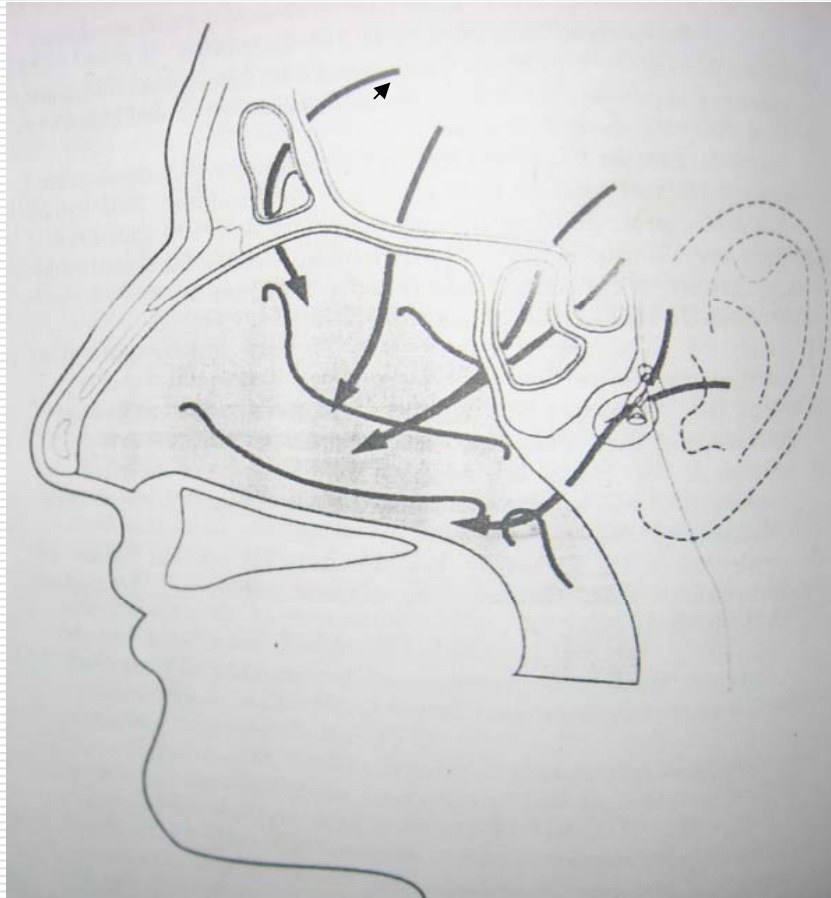
Introduction

- **CSF rhinorrhoea** refers to a **fistula between the subarachnoid space and the nasopharynx** – this may be direct via the anterior cranial fossa and PNS or indirect from the middle or posterior fossa via the eustachian tube with an intact tympanic membrane

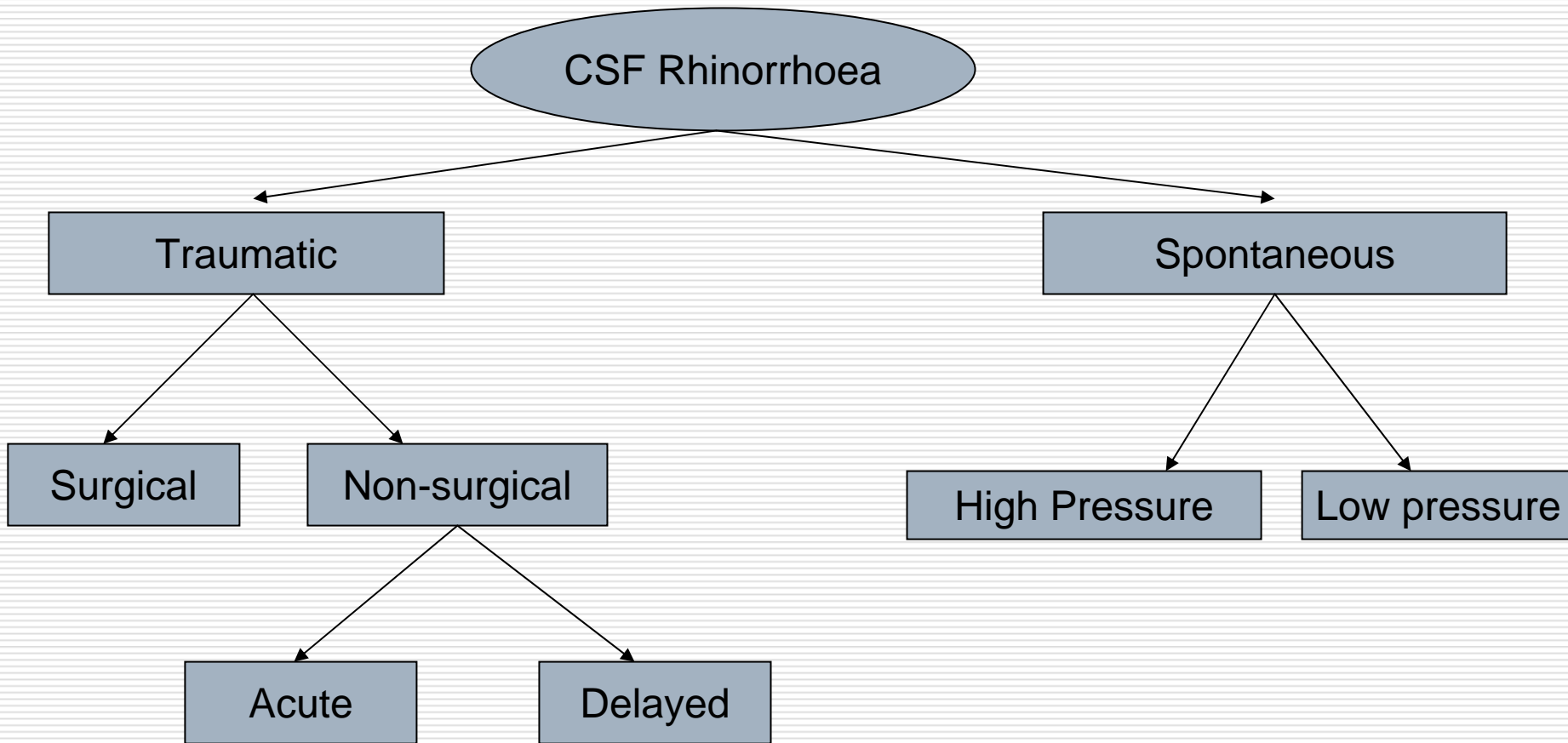
Historical Perspective

- ❑ First described by Galen, 200 B.C.
- ❑ Saintclair Thompson reported the first series of patients with spontaneous leakage in 1889
- ❑ The first well-succeeded surgical approach was attributed to Dandy in 1926, when he sutured the fascia lata over dural defect, on back of the posterior wall of the frontal sinus, by intracranial route
- ❑ In 1964, Vrabec and Hallberg described endonasal approach to repair a CSF leak in the cribriform lamina

Introduction



Causes of CSF rhinorrhoea



Causes of CSF rhinorrhoea

□ **Traumatic** –

- **Acute / Early** – within 1 week

- **Delayed** – month/year later

- Non-surgical-

 - Blunt trauma – Basilar skull fracture

 - Projectile trauma

- Surgical / Iatrogenic / Post-operative leaks-

 - Craniotomy

 - Paranasal sinus surgery

 - Skull base tumour ablation

 - Transsphenoidal surgery

Causes of CSF rhinorrhoea

□ Spontaneous / Non-traumatic –

□ **High-Pressure Flow** -

- Intracranial tumours
- Hydrocephalus

□ **Low-Pressure Flow** –

- Bony erosion, Osteomyelitis, Osteonecrosis
- Sellar atrophy
- Olfactory atrophy / Focal cerebral atrophy
- Congenital defects of skull base
- Pneumatized bone
- Idiopathic

Traumatic CSF rhinorrhoea

- ❑ **MC cause of CSF leak is head trauma, particularly, basilar skull fracture**
- ❑ CSF leaks occur in approximately 3% of all head injuries & 12-30% of basilar skull #, depending upon the accelerative forces
- ❑ Typically begin within 48 hours, and 95% will manifest within 3 months of injury

Traumatic CSF rhinorrhoea

Roofs of ethmoid & the cribriform plate MC site-

- Thinnest area of the ethmoid roof
- Dura tightly adherent to bone in this area
- Natural dehiscence created by Anterior Ethmoidal Artery in the region of lateral cribriform plate
- Prolongation of the subarachnoid space along the olfactory nerve rootlets with subsequent rupture

Traumatic CSF rhinorrhoea

- **Delayed Post-traumatic CSF Leak** –
 - Lysis of clot in the area of fracture
 - Resolution of soft tissue edema
 - Loss of vascularity with necrosis of soft tissue around the wound
 - Delayed increase in ICP after trauma

Post-operative CSF rhinorrhoea

Iatrogenic/Post-operative CSF rhinorrhoea

- Trans-sphenoidal hypophysectomy, Ethmoidectomy, Anterior skull base tumour ablation e.g. olfactory groove meningioma
- May be compounded by altered post-operative CSF flow characteristics or unrecognized/untreated hydrocephalus
- Less likely to resolve spontaneously compared to nonsurgical traumatic cases as the dural and bony defect is large

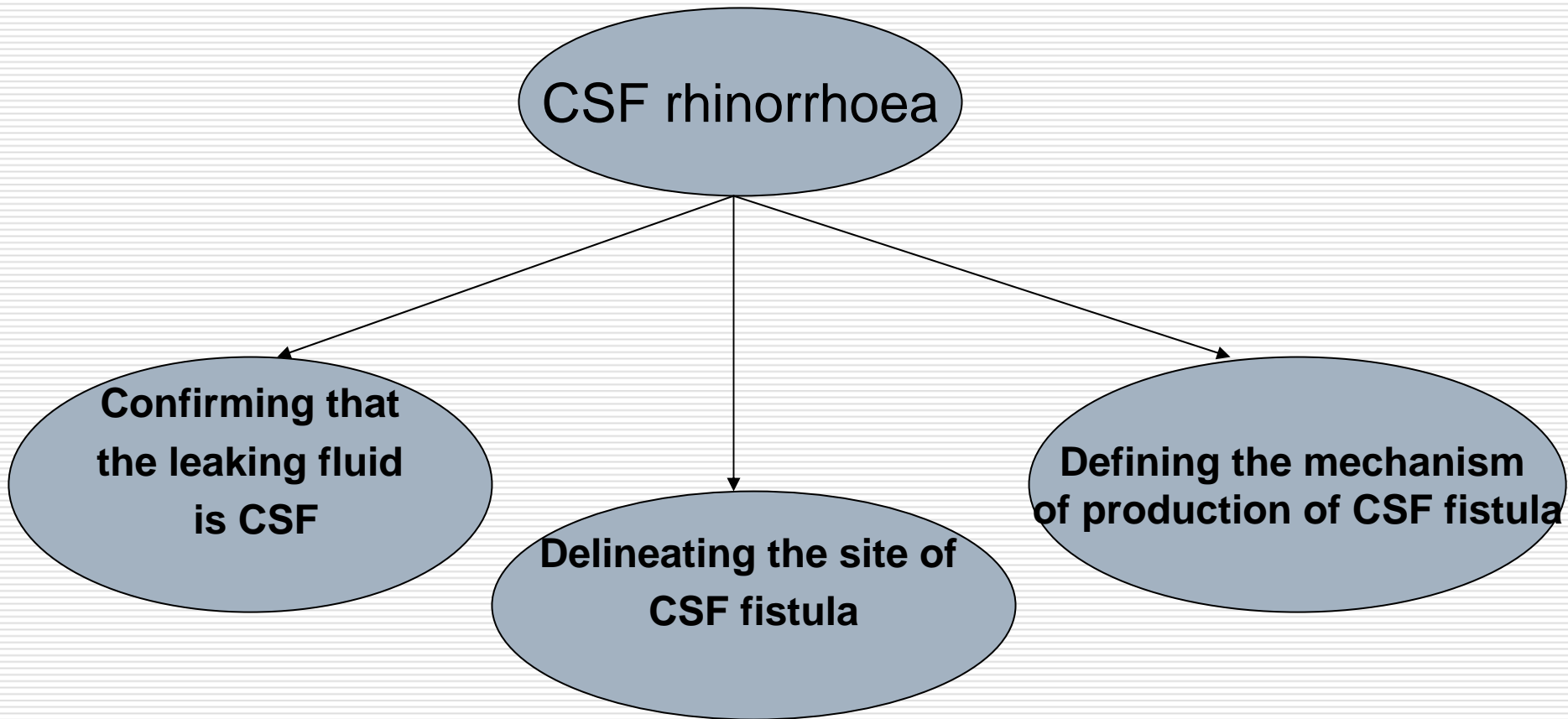
Spontaneous CSF rhinorrhoea

- ❑ Leaks that are explained neither by trauma nor by any other cause
- ❑ Tumours and raised ICP are highly correlated with spontaneous CSF leak
- ❑ Pituitary tumours are the most common neoplastic cause of spontaneous CSF leak, due to sellar erosion

Complications of Untreated CSF fistula

- ❑ **Meningitis** – 3-11 % risk within first three weeks after trauma, overall risk 25%, with 10 % mortality, more with delayed CSF fistula, MC organism isolated is Pneumococcus
- ❑ **Pneumocephalus** – 20-30 %, including life-threatening tension pneumocephalus → indicates open communication with significant risk of meningitis and encephalitis
- ❑ **Cerebral Abscess**
- ❑ **Encephalitis**
- ❑ **Headache**

Diagnostic Approach



Clinical evidence of CSF Leak

- ❑ Unilateral clear watery nasal discharge with a salty taste
- ❑ Dripping in the back of throat
- ❑ Headache –
 - ❑ High pressure – build up over time & relieved by sudden discharge of fluid
 - ❑ Low pressure – postural headache relieved by reclining
- ❑ **Reservoir sign**- Large volume of fluid flowing out of the nose during a change in head position – indicates that a CSF-filled sinus has drained at once
- ❑ Recurrent attacks of headache, fever and meningitis in a patient with history of head trauma → [Look for CSF fistula](#)
- ❑ Provocative Tests – Occult CSF leak can be made manifest with the aid of – Valsalva maneuver
 - Jugular venous compression
 - Flexing the neck in sitting position

Clinical evidence of CSF Leak

- **Target sign/Halo sign** : Pseudochromatographic pattern produced by differential diffusion of CSF admixed with blood or other serosanguinous fluid on filter paper – CSF produces a “Bull’s eye pattern “with blood in the center
 - **Glucose** : CSF - $\geq 50-66$ % serum concn.
Nasal secretion ≤ 10 mg%
Chloride concentration > 110 mEq/L → **Most likely CSF**
- Qualitative spot test – Dextrostix
- Not definitive
 - Negative test excludes the presence of CSF

Clinical evidence of CSF Leak

- Immunological methods –
 - Differentiates between proteins in CSF & those in nasopharyngeal secretions
 - β_2 - transferrin –
 - Highly accurate way of determining presence of CSF; present only in CSF, aqueous humor & perilymph
 - Most sensitive & specific test available to date
 - β -trace protein (Prostaglandin β synthase)

Clinical evidence of CSF Leak

Other contributory evidence-

- Unilateral/bilateral anosmia - defect or leak in the region of cribriform plate
- Imbalance, dizziness, hearing loss, VII nv.dysfunction- temporal bone fracture
- Optic nerve lesion – injury in the region of tuberculum sellae, sphenoid sinus and the posterior ethmoids

Neuroimaging

- ❑ Plain X ray Skull
 - ❑ Basilar skull fracture
 - ❑ Air-fluid level in the PNS
- ❑ CT with bone windows
- ❑ Fine-cut(3mm)CT in both coronal & axial planes with 3D reconstruction
 - ❑ Sphenoid, ethmoid & cribriform plate # best identified on coronal images
 - ❑ Can locate the fistula in more than 50 % cases
- ❑ CT cisternography

Neuroimaging- CT cisternography

- ❑ Water soluble contrast agents- iohexol, metrizamide
- ❑ Procedure-
 - ❑ Baseline CT head done
 - ❑ Contrast injected in subarachnoid space via a C1-C2 cisternal puncture, prone pt placed in Trendelenberg position for 4 min
 - ❑ Table is then made neutral, pt's head extended slightly, and another CT head performed
- ❑ Active leaks-76-100%, Inactive leaks-60%

Neuroimaging

- MRI
- MRI with heavily T2W images & CISS sequences (MR Cisternography)
 - 3D evaluation is done using the CISS technique with 0.7-mm thickness in the sagittal and coronal planes.
 - Highly accurate in localising the site and extent of CSF fistula
 - Non-invasive, No contrast required
- Direct nasal endoscopy-visualizaton of fistula from ethmoid, sphenoid and cribriform plate

Neuroimaging- Radionuclide cisternography

- ❑ Also called as '**Nasal Pledget Staining**'
- ❑ Useful for intermittent CSF fistula
- ❑ Tc⁹⁹ labelled albumin, In¹¹¹ labelled DTPA
- ❑ Placement of cotton-pledgets along areas thought to be harbouring a fistula
- ❑ Slow or intermittent leaks detected by leaving the pledgets in place for 6-48 hrs
- ❑ RI (Radioactivity Index) ratio= $RI_{\text{pledget}} / RI_{1\text{ml of patients blood}}$
- ❑ RI<0.3-Normal, >1.5-CSF leak

Interpretation of Radionuclide cisternography (Nasal Pledget Staining)

Location of stain	Probable site of fistula
Anterior nasal	Cribriform plate or anterior ethmoidal roof
Posterior nasal or sphenoethmoidal	Posterior ethmoid or sphenoid sinus
Middle meatus	Frontal sinus
Below posterior end of inferior turbinate	Eustachian tube (middle fossa)

Neuroimaging- Tracer study

- Useful for intraoperative localization of CSF fistula
- Principle- Ability to retrieve extracranially a tracer substance injected into the CSF
- Fluoroscein, Indigo-carmin

Management of Traumatic CSF rhinorrhoea

Most traumatic CSF leaks stop on their own-

- 35 % leaks stopped within 24 hours
- 68 % within 48 hours
- 85 % within 1 week



Conservative Management

(Mincy JE: Post-traumatic CSF fistula of the frontal fossa.
J Trauma 6:618,1966.)

Conservative management

- Position – elevate head 30-45° for cranial leaks
- Avoid sneezing, coughing, straining
- Monitor carefully for neurological deterioration- meningitis or pneumocephalus
- ?Antibiotics– for prevention of meningitis
- Pharmacological adjuvants – Diamox, Frusemide

Role of Lumbar CSF drainage

- ❑ Rationale – Granulation tissue can seal the fistula provided that the leak has stopped
- ❑ Indicated if positioning and diamox alone does not significantly decrease CSF leak within 24 hours
- ❑ CSF drainage to be continued for 3 – 5 days after stoppage of leak to allow healing

Role of Lumbar CSF drainage

Complications –

- Over drainage of CSF – pneumocephalus, intracranial haemorrhage
- High CSF protein concentration - Blockage
- Meningitis – incidence can be reduced by tunneling the external catheter and by prophylactic antibiotics
- Broken catheter tip
- Dural-cutaneous fistula -
 - Stitch
 - Epidural blood patch

Indications of Surgical Intervention

- ❑ Recurrent attacks of meningitis with continuing leak despite conservative management
- ❑ Patients with enlarging pneumocephalus (> 2 cc persistent intracranial air - significant) despite conservative treatment
- ❑ Acute traumatic or post-operative leaks that recur or persist after 10-13 days of conservative management including Lumbar CSF drainage
- ❑ Proven intermittent or delayed leaks
- ❑ High pressure leaks with hydrocephalus

Indications of Surgical Intervention

- Radiological appearances that indicate a low probability of natural dural repair-
 - Erosion, destruction or severe comminution of skull base or sinuses
 - Intracranial spikes of bone
 - Soft tissue between the bony edges
- Leaks associated with congenital dysplasia of brain, skull base; particularly after a bout of meningitis

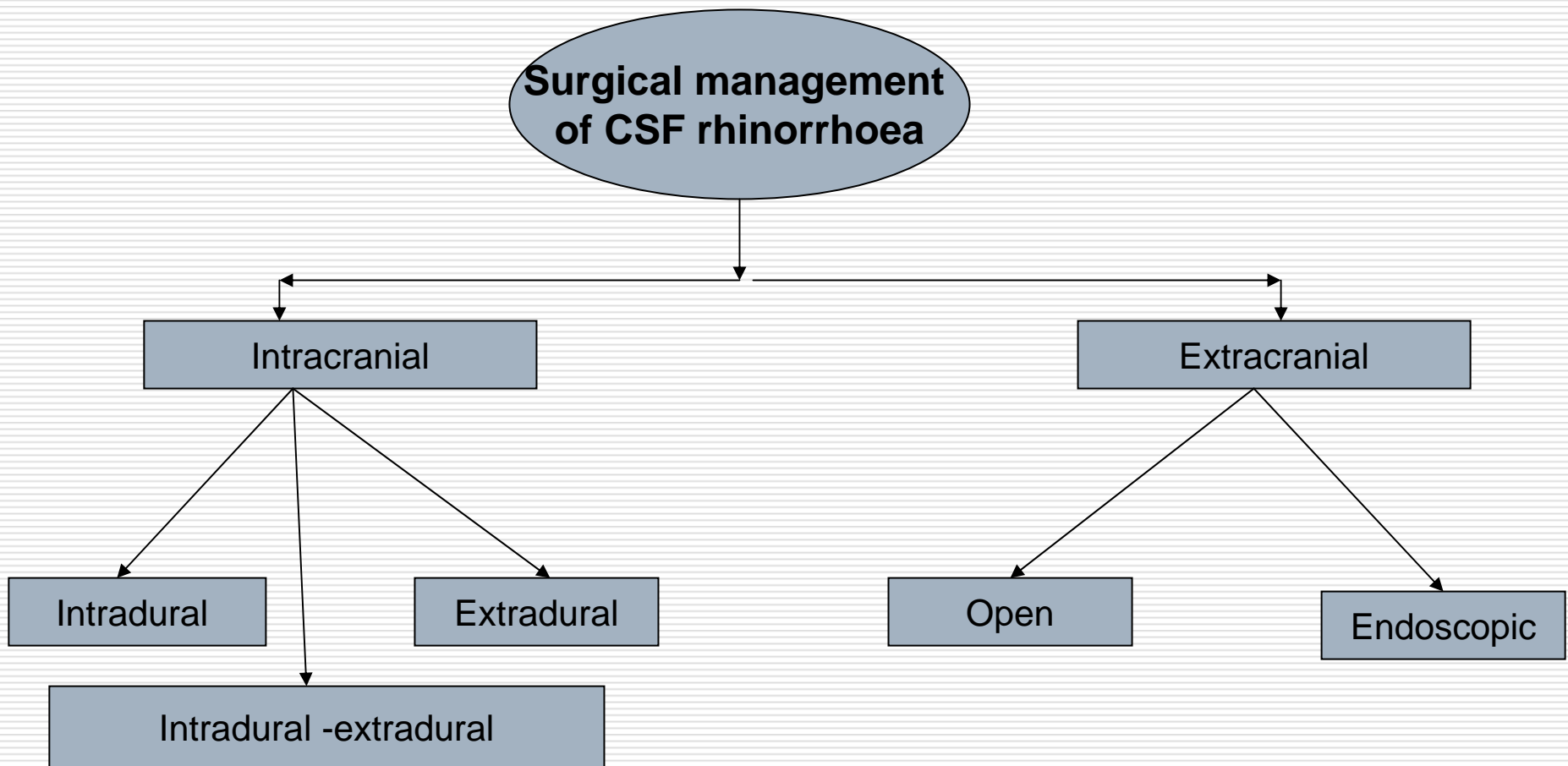
Indications of Surgical Intervention

- ❑ Leaks caused by high-energy missile wounds
- ❑ High volume leaks through sella and petrous bone are particularly resistant to conservative management

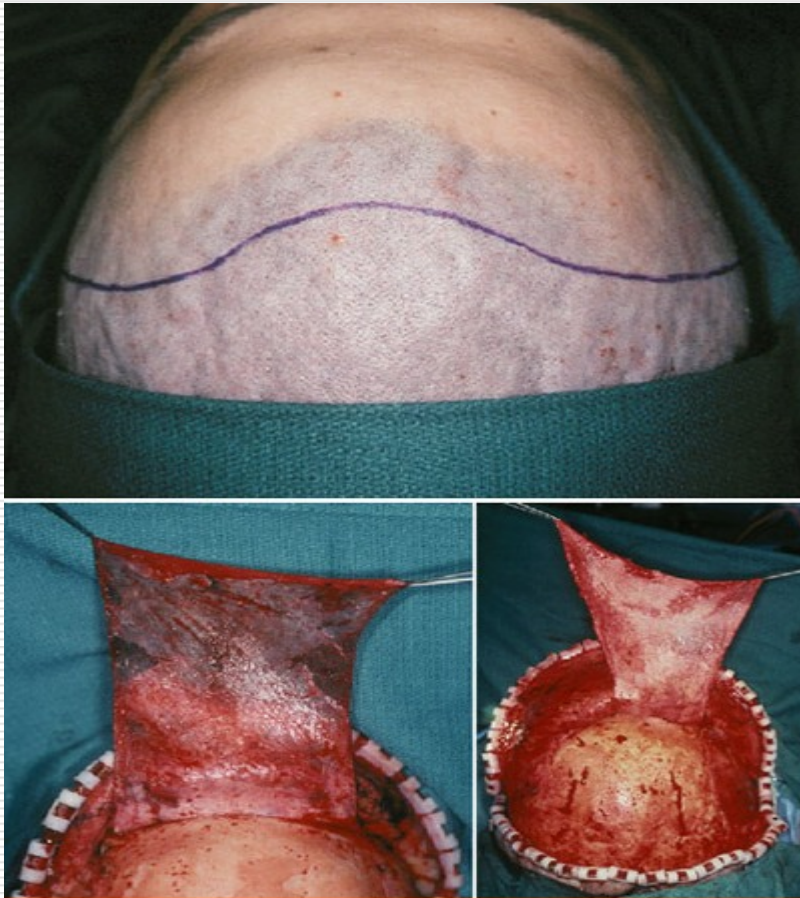
General Principles

- Treat meningitis and rule out hydrocephalus before embarking on any surgical procedure**
- Careful identification of the site and extent of the dural defect
- Dissection of the bony and dural defect
- Direct dural repair if possible
- Closure using a graft(\pm glue), if direct dural repair is not possible

Surgical management



Intracranial approaches



- ❑ Position- Supine with head slightly extended to allow frontal lobes to fall backwards
- ❑ Head-end of table elevated by 15° to facilitate venous drainage
- ❑ Bicoronal skin flap
- ❑ Elevate the pericranium as a separate layer for subsequent anterior cranial fossa repair
- ❑ Care taken to preserve supraorbital nerves- conversion of foramen into a groove

Intracranial approaches

- Very important to fashion the bone flap very low to clearly visualize the floor of anterior cranial fossa & the site of leak
- Dealing the frontal sinus
- Extradural or Intradural

Intracranial , **extradural** exploration - Limitations

- ❑ Dural tears virtually inevitable in the course of dissection, makes identification of “original” traumatic CSF fistula more difficult
- ❑ Areas of cerebral tissue herniation into bony defects cannot be easily visualized
- ❑ Permanent dural repair is not reliably achieved

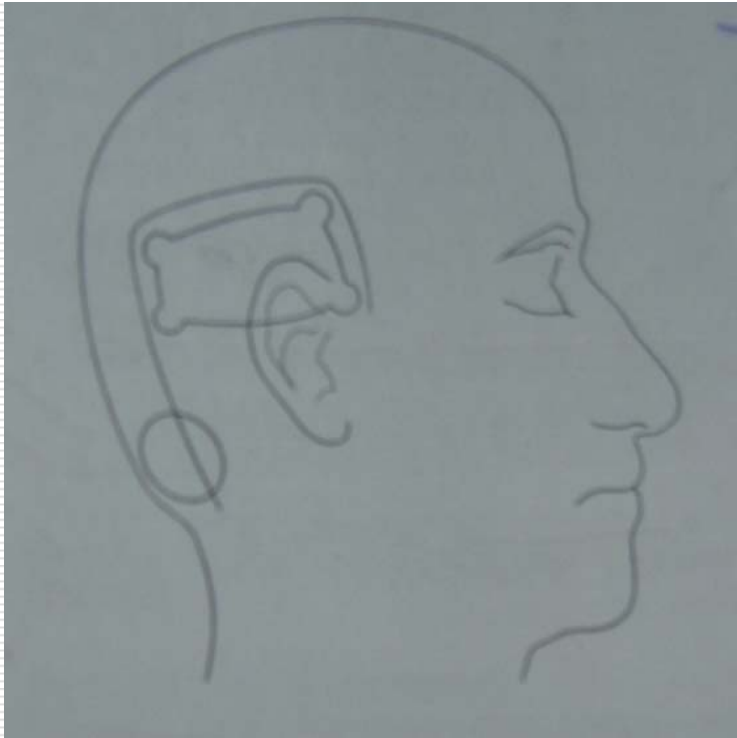
Intracranial , **intradural** exploration

- ❑ Excellent exposure of the entire anterior cranial fossa way back to the lateral aspects of sphenoid wings and posteriorly upto the planum & anterior clinoid processes
- ❑ Dura should be opened far anteriorly, which may require anterior third of SSS to be ligated and cut
- ❑ Falx must also be cut to provide full exposure
- ❑ Identification –
 - ❑ Areas of parenchymal brain contusion
 - ❑ Brain may be adherent to or herniated through the defect
 - ❑ Identification with the help of positive pressure ventilation

Intracranial , **intradural** exploration - Indications

- ❑ Once located, the fistula is to be packed with a plug of fat – to be reinforced with a dural patch graft from autologous pericranium, temporalis fascia or fascia lata + biological glue
- ❑ **If a discrete fistula cannot be identified-**
 - ❑ Cover the entire anterior cranial fossa floor with a large pericranial graft all the way upto planum sphenoidale & cover both cribriform plates + biological glue
- ❑ The use of fibrin glue have improved the success of operative closure and is strongly recommended.

Management of Petrous # with CSF otorrhoea/otorhinorrhoea



- ❑ Longitudinal # rarely need repair
- ❑ Subtemporal craniotomy and extradural approach
- ❑ If mastoid air cells are opened, they are plugged with bone wax
- ❑ Repair of the defect with fascia and glue

CSF shunting(VP / TP shunt)

- **Hydrocephalus must be excluded first in any case of CSF rhinorrhoea, which fails to respond to conservative management**
- Carried out in conjunction with anatomic repair of a fistula or resection of a mass lesion in the face of hydrocephalus
- Small leaks that cannot be identified

Extracranial, **extradural** approach (Open / Endoscopic)

□ **Considered for-**

- Sphenoid
 - Parasellar
 - Posterior wall of frontal sinus
 - Cribriform / ethmoid
 - Petrous
- CSF fistula

□ **Unsuitable for-**

- Bilateral fistula
- Where site of CSF leak is uncertain
- Where intracranial debridement of brain and brain is necessary

Extracranial, **extradural** approach (Open / Endoscopic)

- ❑ Discrete, clearly defined normal pressure leaks from anterior cranial fossa including cribriform plate and adjacent ethmoid
- ❑ Post-operative CSF leak after Transsphenoidal surgery, not controlled by conservative management
- ❑ Fractures that abut on an air sinus, particularly when the bony defect is limited to the cranial wall of the sinus

Extracranial, **extradural** approach (Open / Endoscopic)

□ **Advantages-**

- No brain retraction
- No additional risk of anosmia
- Operation need not be delayed by brain swelling

□ **Disadvantages-**

- Localization of fistula must be very precise
- Graft is placed extradurally and not tamponaded by the brain

Extracranial open approaches

□ **Trans-sphenoidal repair for CSF rhinorrhoea after pituitary surgery**

- Sublabial, transseptal or endonasal route
- Sphenoid mucosa is stripped and repair is performed with fascia lata & secured with fibrin glue
- Sphenoid sinus packed with fat and glue ± autologous bone/ cartilage to reinforce the opening of sphenoid sinus

([Tamasauskas A](#) et al. Management of cerebrospinal fluid leak after surgical removal of pituitary adenomas . Medicina (Kaunas). 2008; 44(4):302-7)

Extracranial open approaches

External ethmoidectomy-

- Most common extracranial approach to fistulas of the cribriform and ethmoid regions
- Naso-orbital (Lynch-howarth incision) midway between nasal dorsum and medial canthus along the curvature of nasofacial crease
- Ethmoidectomy
- Tracer to identify the site of leak
- Repaired with fascia + glue + pedicled mucoperiosteal flap + supported by nasal packing

Transmastoid approach-

- For # petrous bone involving tegmen tympani with intact hearing

Other extracranial techniques

- **Primary repair of facial fractures**
(with sinus repair and ablation as necessary)
- **Frontal osteoplastic sinusotomy** (repair of posterior sinus wall or cranialization of sinus & packing - in case of simple fracture through posterior wall of frontal sinus without evidence of comminution of skull base or significant cerebral contusion)

Transnasal Endoscopic repair

- ❑ Clear anatomical exposure of the roof of the nasal and sinus cavities by the endoscope
- ❑ Excellent field of vision, allowing exact localization of the leak
- ❑ The ability to clean mucosa from the bony defect precisely.
- ❑ Accurate position of the graft material over the defect.

Transnasal Endoscopic repair

- Variety of options for techniques to repair the defect of the anterior skull base, but the principle concept is still the same: "water-tight closure".
- Mucoperiosteal flaps from various donor sites (especially the nasal septal) was rotated to the leak area to seal the defect, with a success rate of 95-100%

Transnasal Endoscopic repair

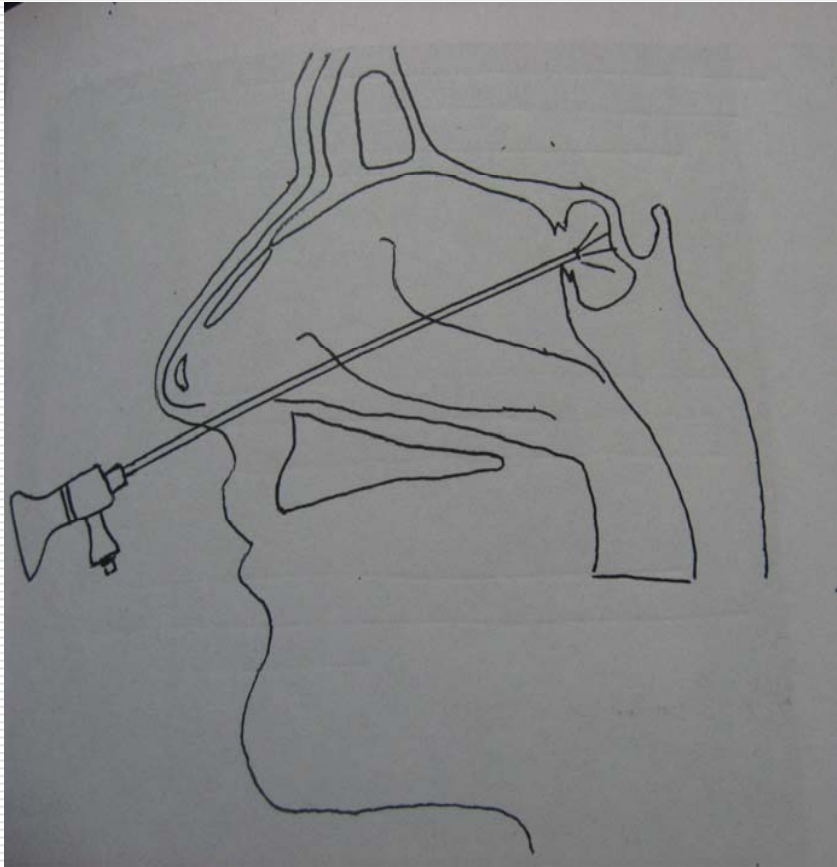
- ❑ **Small sized defect(< 0.5 cm) -mucosal graft or flap**
- ❑ **Larger defect(> 0.5cm)- bone or cartilage graft.** Septal cartilage is better as a free graft because of its property of pliability, which makes it easier to insert through the skull base defect
- ❑ There is no limitation for endoscopic repair of sphenoid sinus fistula as regards to the size of the bony defect
- ❑ However, ethmoid roof defect > 1.5cm is considered a relative contraindication to endoscopic repair

Transnasal Endoscopic repair- Sphenoid sinus

□ Procedure-

- Nasal cavities infiltrated with LA
- Endoscopic sphenoidotomy accomplished through transetmoid approach
- Identify the defect, remove any residual mucosa as it prevents adhesion of the graft
- Fascia lata with fat graft harvested
- Fascial graft placed over the defect + glue + fat graft
- Reinforced with surgical gelfoam + nasal pack

Transnasal Endoscopic repair – Sphenoid sinus defect



- Endoscopic approach to sphenoid sinus defect

Transnasal Endoscopic repair – Cribriform plate defect

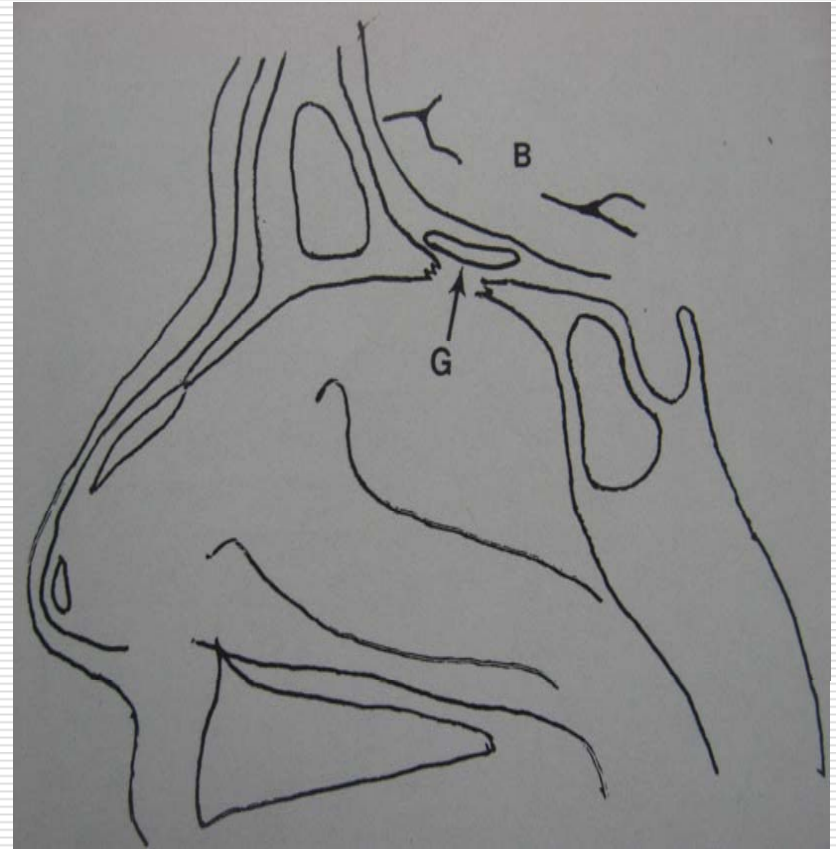
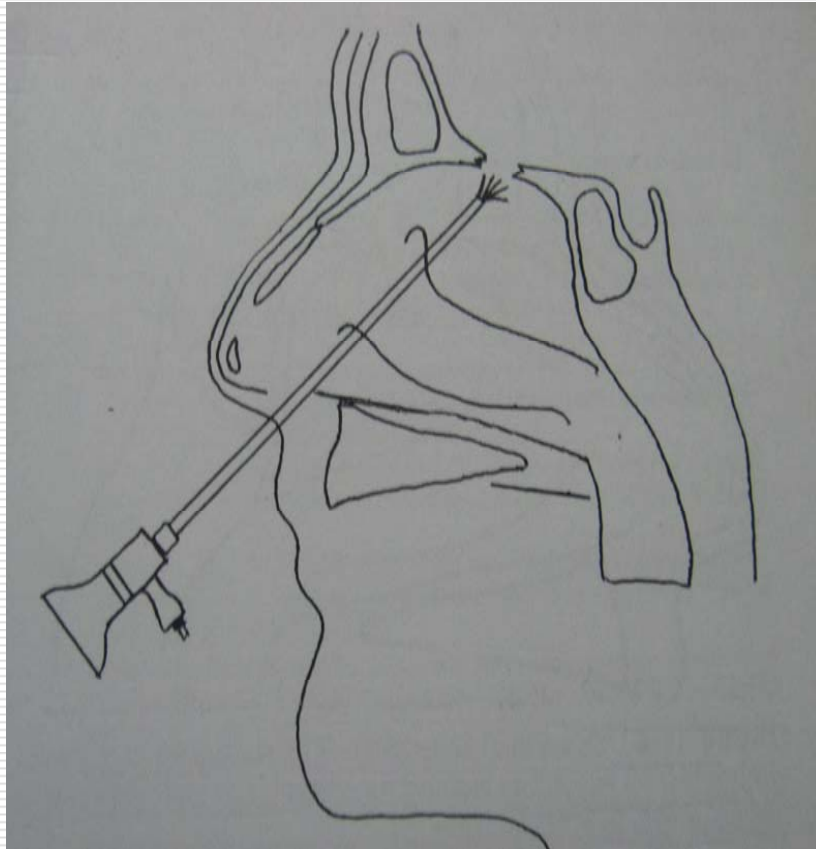
- ❑ Approach same as for transnasal endoscopic sphenoid sinus repair
- ❑ Complete ethmoidectomy performed to expose defects of anterior skull base
- ❑ Identify the defect, remove any residual mucosa as it prevents adhesion of the graft
- ❑ Mucosal graft or a composite mucosa-turbinate graft harvested from opposite nasal cavity
- ❑ A free bone/turbinate graft may be placed on the intracranial side of the bony defect between dura & skull base (Underlay) or can be placed directly over the defect (Onlay) & secured with fibrin glue

Transnasal Endoscopic repair

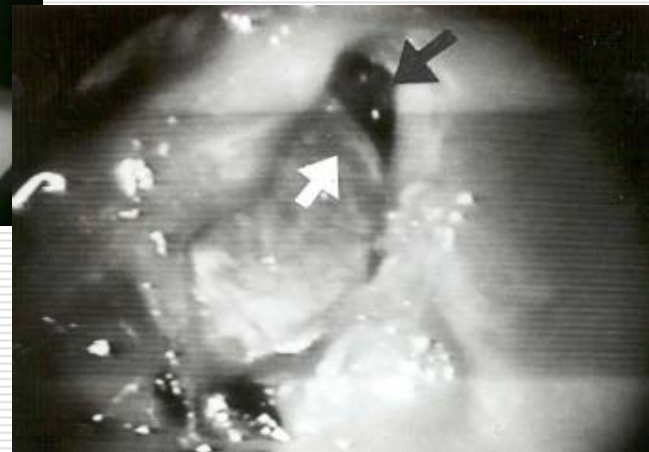
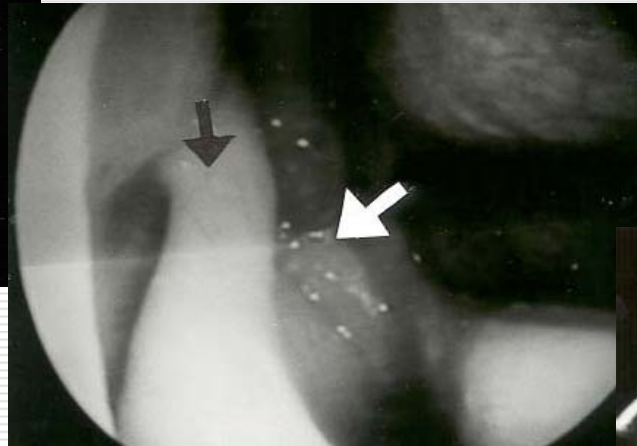
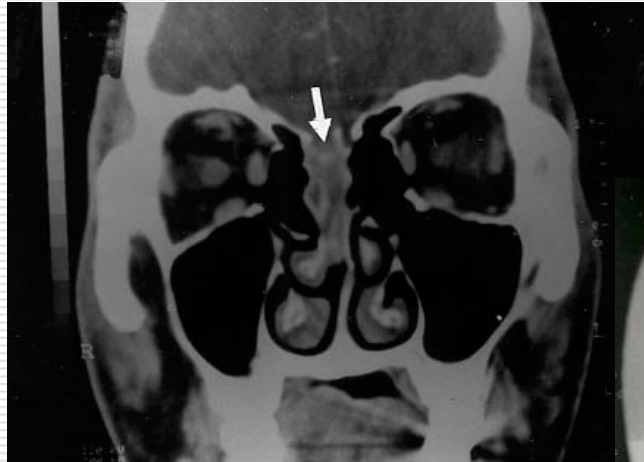
- Success or failure depends upon
 - Surgeon's experience
 - Correct localization of fistula pre and intraoperatively
 - Raised ICP
- No statistical difference in results based on
 - Type of graft (Free vs Pedicled, mucosa vs fascia, muscle vs fat)
 - Underlay or onlay graft
 - Use of lumbar drain post-operatively

([Zweig JL et al](#). Endoscopic repair of CSF leaks to the sinonasal tract: Predictors of success. Otolaryngol Head Neck Surg 123: 195-201, 2003.)

Transnasal Endoscopic repair – Cribriform plate defect



Transnasal Endoscopic repair



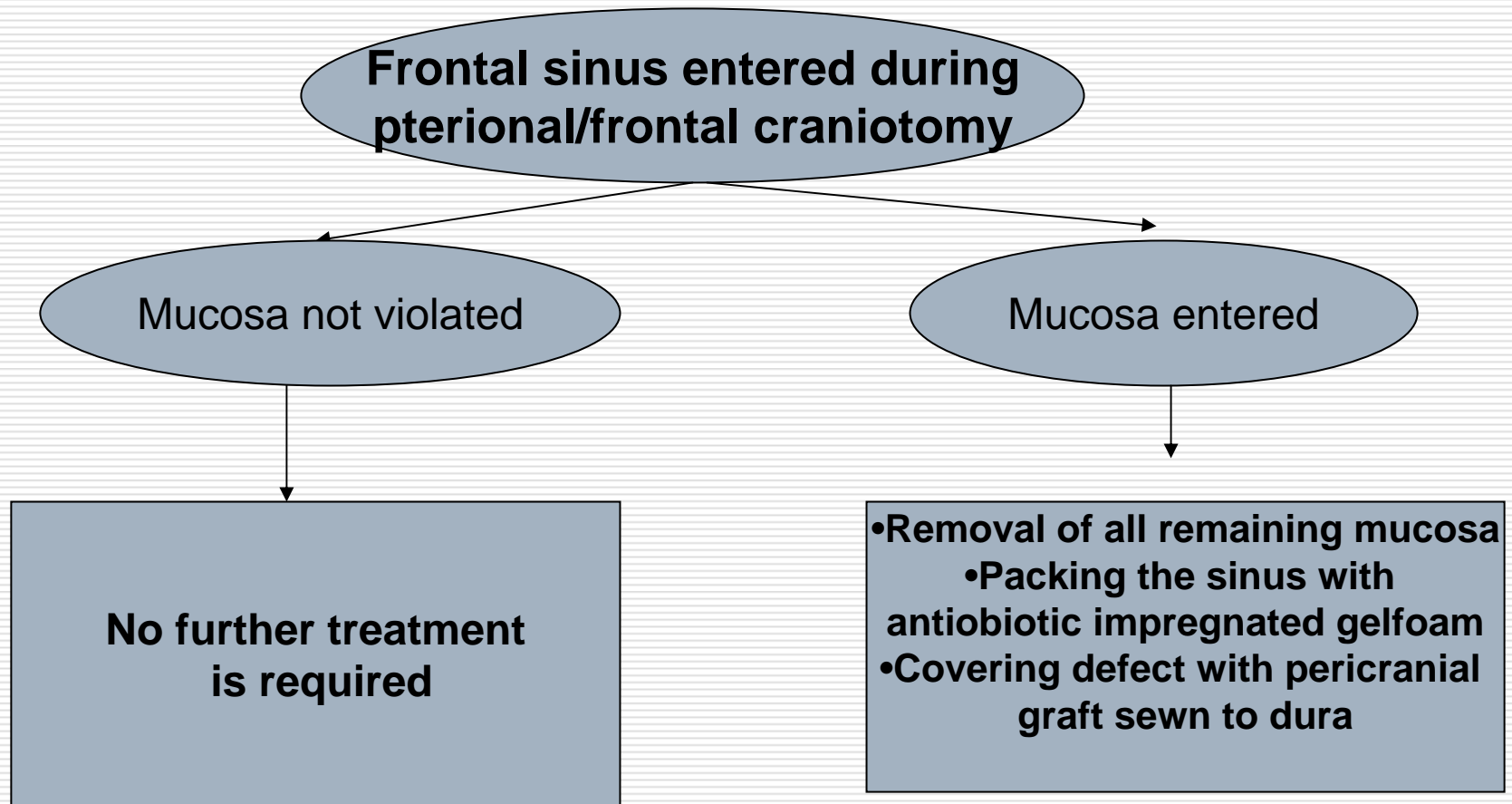
Surgical approaches to skull base with inherently higher risk of developing post-operative CSF rhinorrhoea

- ❑ Subfrontal approach with breach of frontal sinus
- ❑ Anterior skull base lesion (e.g. olfactory groove meningioma)
- ❑ Transsphenoidal
- ❑ Transtemporal or suboccipital approach to acoustic tumours

Prevention of CSF leaks

- Anterior cranial fossa-
 - Management of frontal sinus
 - Subfrontal approaches
- Middle cranial fossa-
 - Trans-sphenoidal
- Posterior cranial fossa-
 - Suboccipital or transtemporal approach to acoustic neuroma

Management of frontal sinus

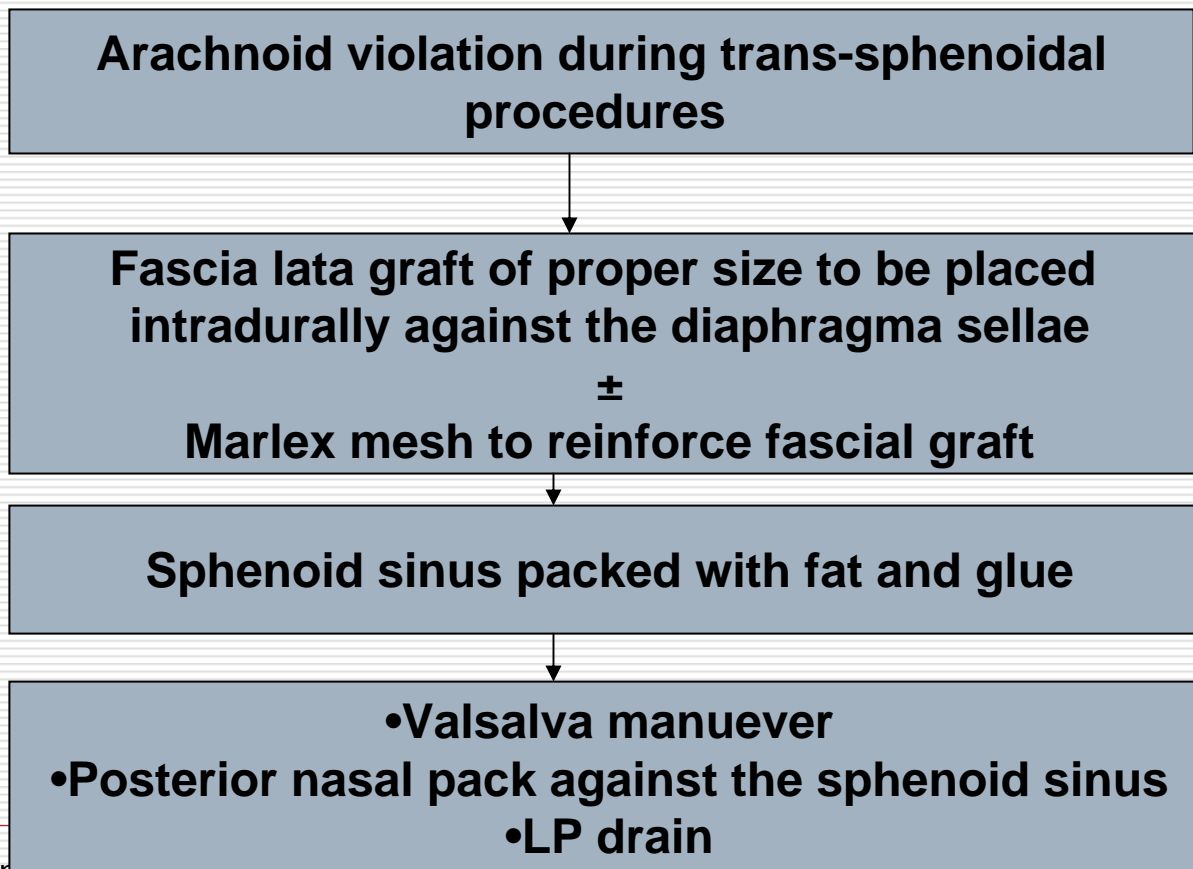


Subfrontal approaches

- ❑ Anterior skull base lesions such as meningioma or primary nasopharyngeal tumours may require resection of underlying dura or bone
- ❑ **Small defect**-Packing with fat/muscle and covering with fascia+biological glue
- ❑ **Large defect**- Extensive reconstruction with fascial graft + biological glue ± autologous bone graft / methylmethacrylate / tantalum mesh
- ❑ Elevate the periosteum as a separate flap at the start of procedure to create a periosteal flap layer for repair of skull base bony/dural defect

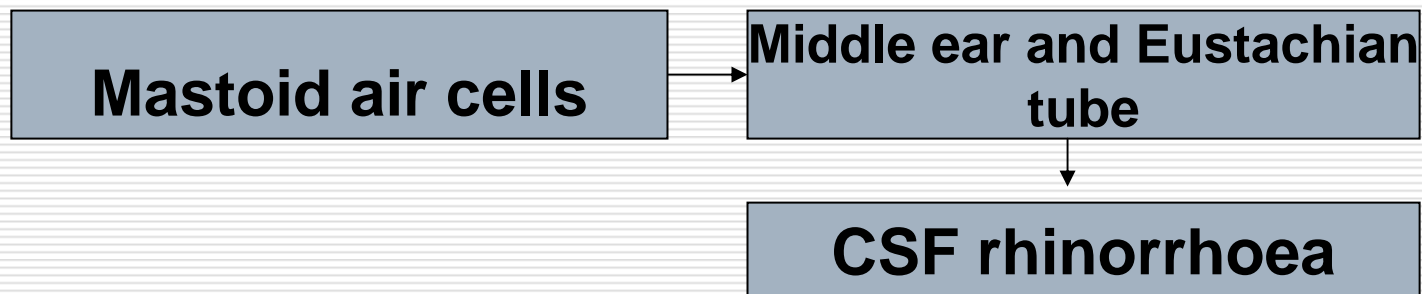
Trans-sphenoidal Approach

□ Incidence of CSF leak-1.4 to 6.4%



Acoustic Neuroma surgery

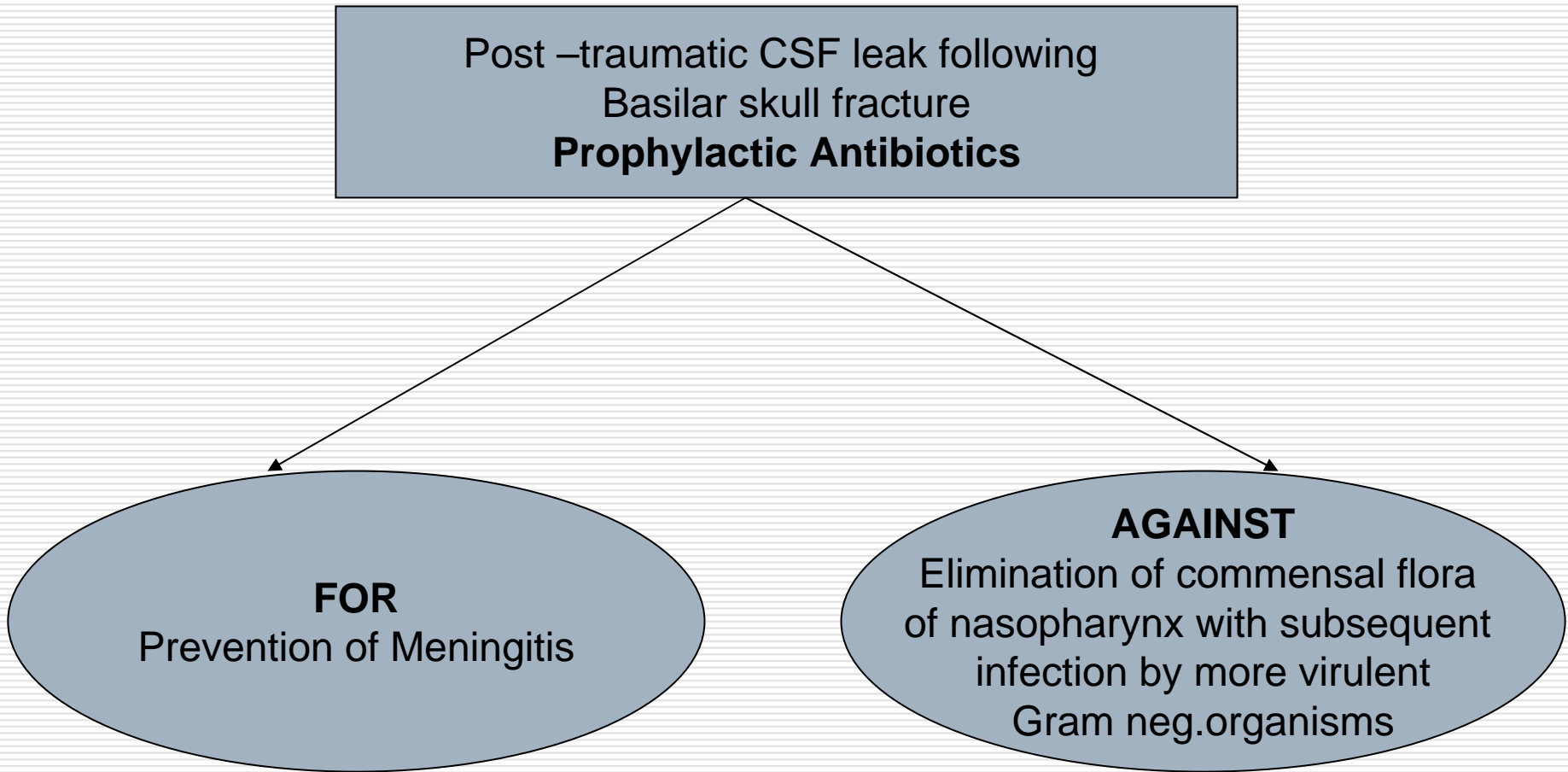
- ❑ Incidence – 6-30 %
- ❑ Translabyrinthine, Suboccipital, Transsigmoid approach
- ❑ Well- pneumatized petrous bone may predispose to leakage during drilling of posterior wall of meatus



Acoustic Neuroma surgery

- ❑ Violation of mastoid air cells- Seal with bone wax and packing with fat & muscle
- ❑ Transmastoid approach for CSF leak localization
- ❑ Free adipose tissue autograft in the bone defect
- ❑ Careful closure of fascial, subcutaneous & skin layers

Controversies in Management - Routine Antibiotic prophylaxis



Controversies in Management - Routine Antibiotic Prophylaxis

□ FOR

↓
Brodie HA. Prophylactic antibiotics for posttraumatic cerebrospinal fluid fistulae. **A meta-analysis**. Arch Otolaryngol Head Neck Surg. 1997 Jul;123(7):749-52

↓
2.5%(6/237). who received prophylactic antibiotics developed meningitis compared to 10 % (9/87) who did not receive prophylactic antibiotics

↓
Statistically significant reduction

□ AGAINST

↓
Eljamel MS. Antibiotic prophylaxis in unrepaired CSF fistulae. Antibiotic prophylaxis in unrepaired CSF fistulae. Br J Neurosurg. 1993;7(5):501-5.

↓
Risk of meningitis was 7.6% (8/106) in the treated and 11.9%(13/109) in the untreated group↓

- **Statistically non- significant reduction**
- **More cases of Gram-negative infection and of partially-treated meningitis in the treated group.**

Controversies in Management - Routine Antibiotic Prophylaxis

- [Klastersky J](#), [Sadeghi M](#), [Brihaye J](#). Antimicrobial prophylaxis in patients with rhinorrhea or otorrhea: **a double-blind study**. Surg Neurol. 1976 Aug; 6(2):111-4.



A total of 52 patients was studied, 26 in each treatment group. Meningitis developed in one patient in the placebo group.



Statistically non-significant

CURRENT RECOMMENDATION

Routine prophylactic antibiotics are no longer recommended in Post-traumatic CSF leak

Controversies in Management - CT Cisternography vs MR Cisternography

- The sensitivity in detecting CSF fistulae with MR cisternography (CISS: 93.6 %) was higher than with CT cisternography (72.3 %). Although the localization of CSF fistulae always proved possible with MR cisternography, this could only be accomplished with CT in 70 % of cases.

([Eberhardt KE](#), [Hollenbach HP](#), [Deimling M](#), [Tomandl BF](#), [Huk WJ](#). MR cisternography: a new method for the diagnosis of CSF fistulae. *Eur Radiol.* 1997;7(9):1485-91.)

Controversies in Management - CT Cisternography vs MR Cisternography

- The sensitivity and specificity of the MR method-**T2*-weighted 3D-CISS sequence** (88.9% and 95.1%) is higher compared with CT cisternography (77.8% and 87.8%). **The MR method is superior to CT cisternography, is noninvasive, the administration of contrast agent is no longer necessary.**

([Eberhardt KE](#) et al. MR diagnosis of cerebrospinal fluid fistulas using a 3D-CISS sequence Rofo. 1997 Dec;167(6):605-11)

Controversies in Management - Open/ Endoscopic Repair

- ❑ The conventional approaches for repairing to anterior skull base defect are the extracranial route (naso-orbital incision) or craniotomy with pericranial flap
- ❑ These approaches to repair the defect of the anterior skull base have a variable success rate of 60 to 80 percents
- ❑ The morbidity associated with craniotomy such as a loss in the ability to smell and prolonged hospitalization has made the endoscopic approach an alternative option.
- ❑ In the series of endoscopic repair, the success rate was 85.7% after the initial procedure and 100% after a second one.

(Mattox DE, Kennedy DW. Endoscopic management of cerebrospinal fluid leaks and encephaloceles. Laryngoscope 1990; 100: 858-62.)

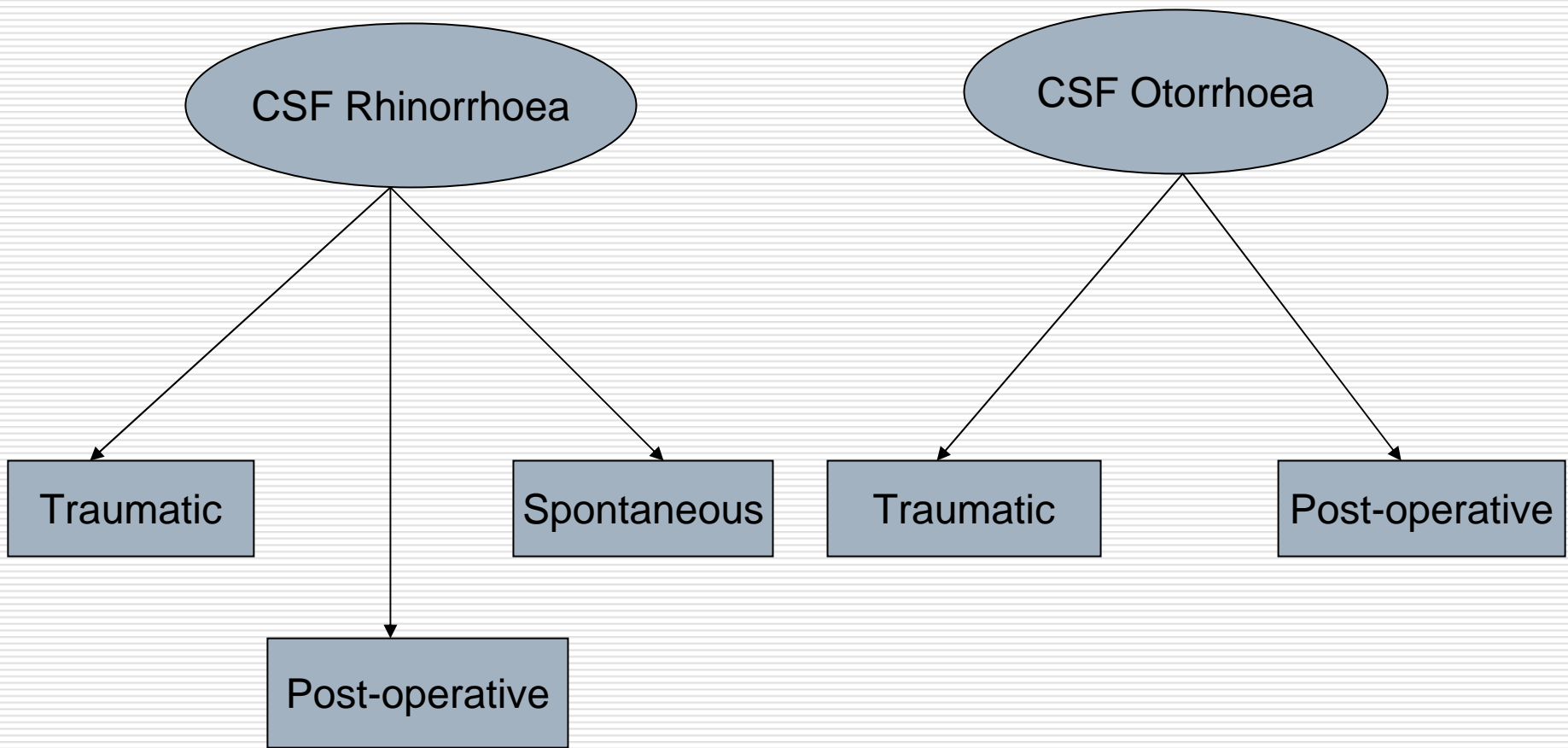
Controversies in Management - Open/ Endoscopic Repair

- ❑ **The endoscopic approach should be considered as the preferred method if the skull base defect is endoscopically accessible.**
- ❑ Endoscopy offers the advantage of **reduced hospitalization and better visualization**
- ❑ Craniotomy approach is still the back-up procedure if the endoscopic one fails

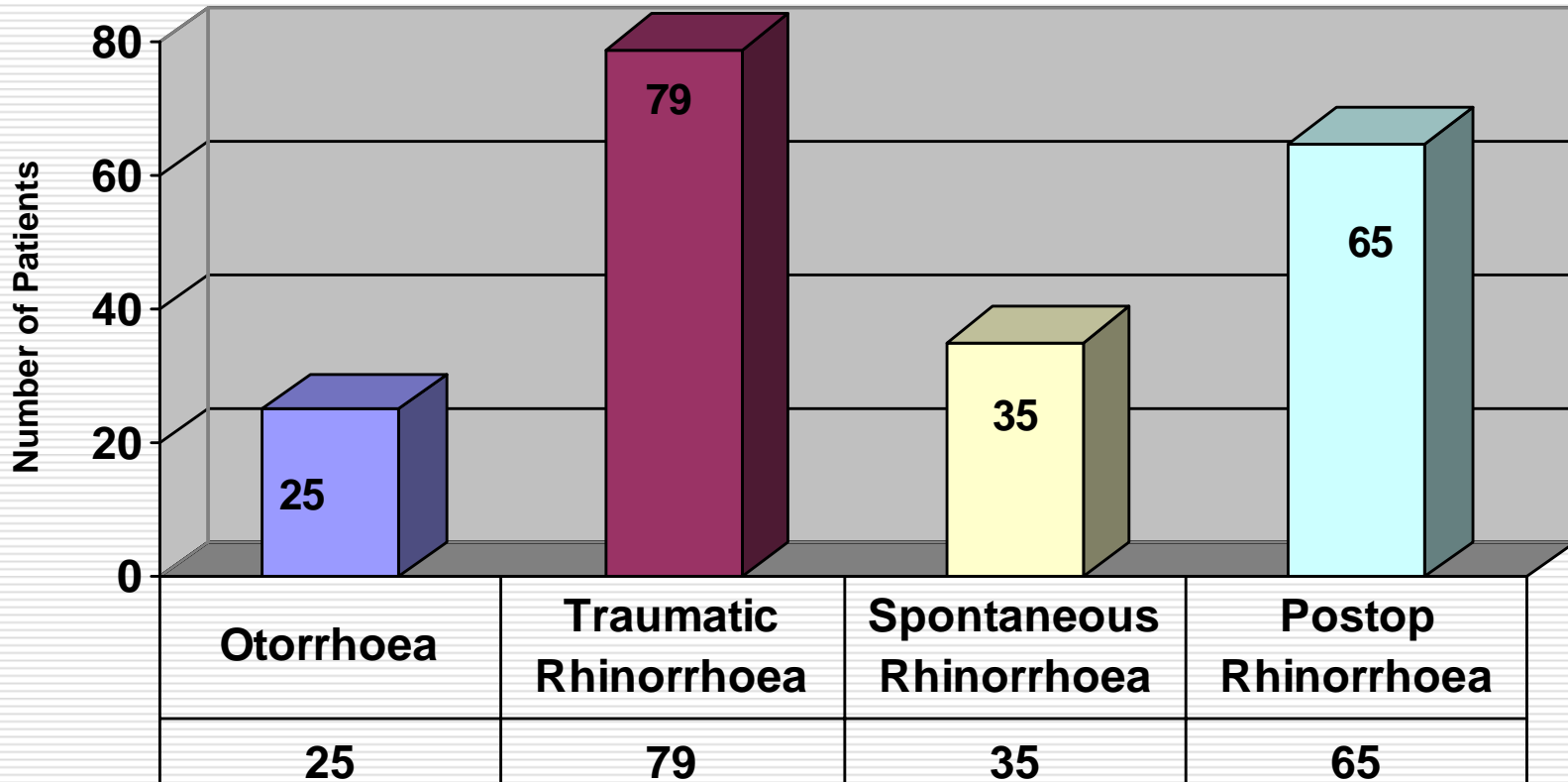
AIIMS Experience

- ❑ Retrospective analysis
- ❑ Study period - January 2001 to December 2006, spanning a period of 6 years.
- ❑ **Total no. of patients – 204,**
CSF rhinorrhoea – 179
CSF otorrhoea – 25
- ❑ Patients with minor traumatic CSF leaks which ceased spontaneously within first 48 hours were excluded.

AIIMS Experience



AIIMS Experience



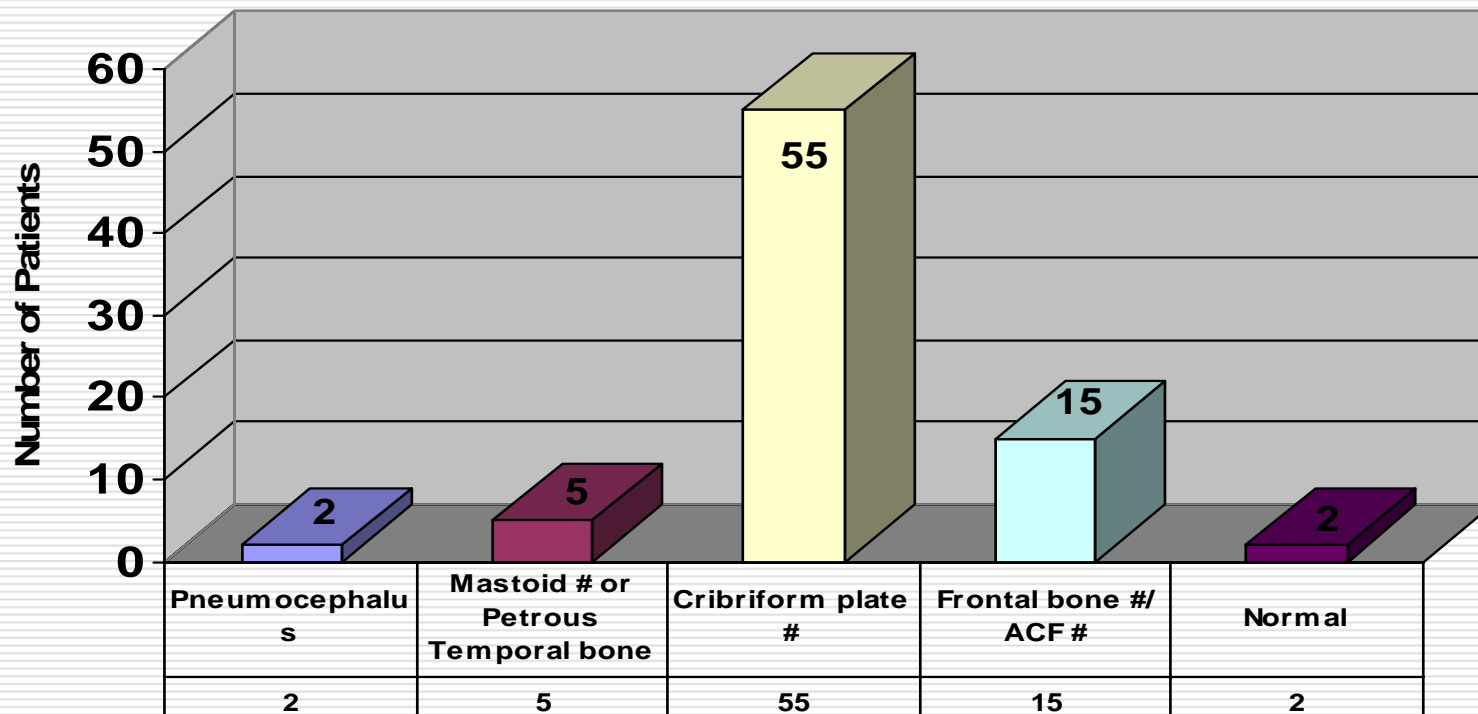
AIIMS Experience

	Traumatic CSF Rhinorrhoea	Spontaneous CSF Rhinorrhoea	Post-op CSF Rhinorrhoea	CSF Otorrhoea
Total number of patients	79	35	65	25
Mean Age	26.3 Years	38.7 Years	36 Years	28.2 Years
Sex ratio (M:F)	6.1:1	0.52:1	0.9:1	2.1:1
Unilateral / Bilateral	62/17	28/7	20/45	25/0

AIIMS Experience – Traumatic CSF rhinorrhoea

- n=79
- Maximum number of patients [33(41.77%)] presented immediately after trauma, followed by 9(11.3%) patients who presented within first two weeks following trauma.
- 11 (13.9%) patients had history of meningitis.

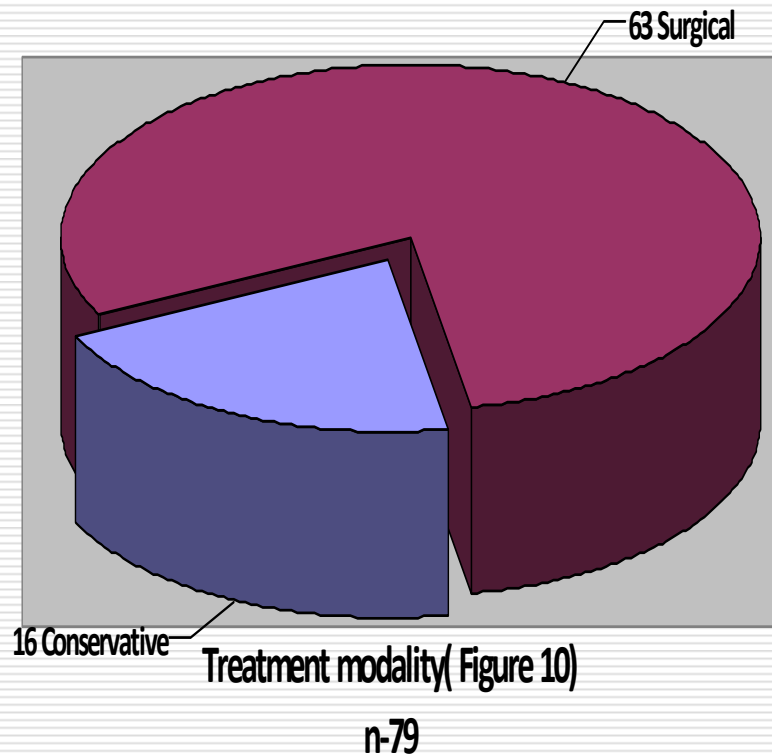
AIIMS Experience – Traumatic CSF rhinorrhoea



Radiological findings(Figure 8)

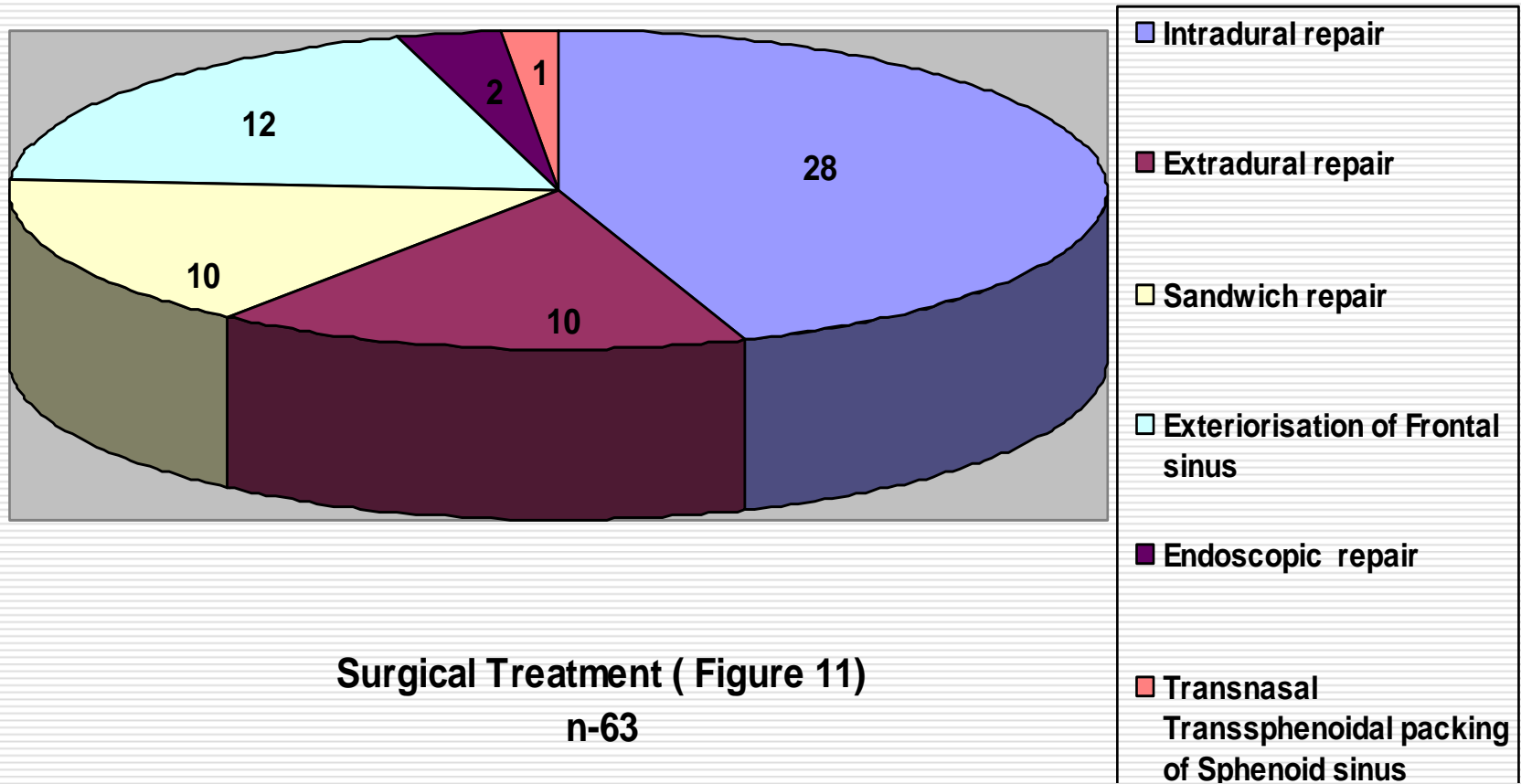
n-79

AIIMS Experience – Traumatic CSF rhinorrhoea



- The patients were managed conservatively or surgically based upon the time of presentation, magnitude of leak, history of meningitis or history of recurrences.
- Five (31.2%) patients were treated with bed rest, acetazolamide, and frusmide alone, while 11 (68.7%) patients were treated with additional lumbar CSF drain.

AIIMS Experience – Traumatic CSF rhinorrhoea



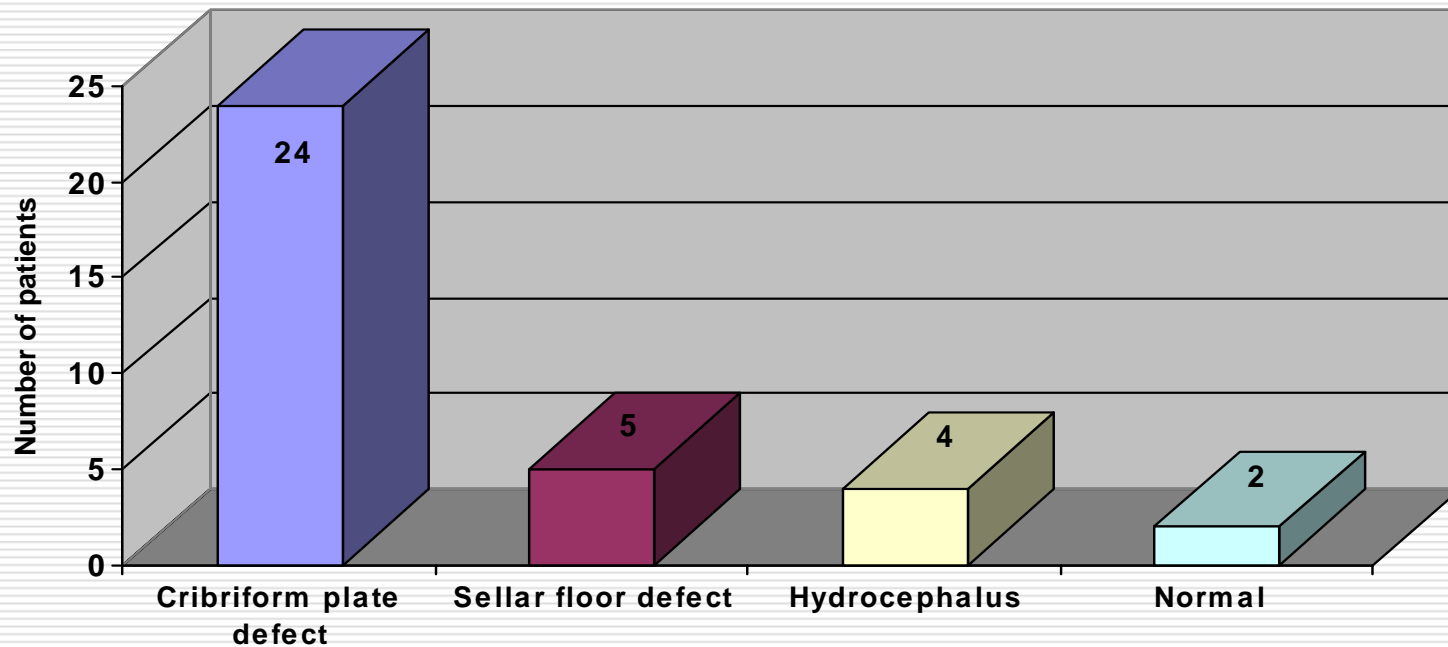
AIIMS Experience – Traumatic CSF rhinorrhoea

- **Complications:** 12 (15.1%) patients developed postop meningitis
- **Follow-up and outcome :**
 - Mean follow up -11 m(1 m-4 yrs)
 - 65 (82.27%) - no further leaks,
 - 6(7.59%) - recurrence of CSF leak
{HCP was associated, 2/6 required re-surgery}
 - 1(1.26%) patient died of fulminant post operative meningitis

AIIMS Experience – Spontaneous CSF rhinorrhoea

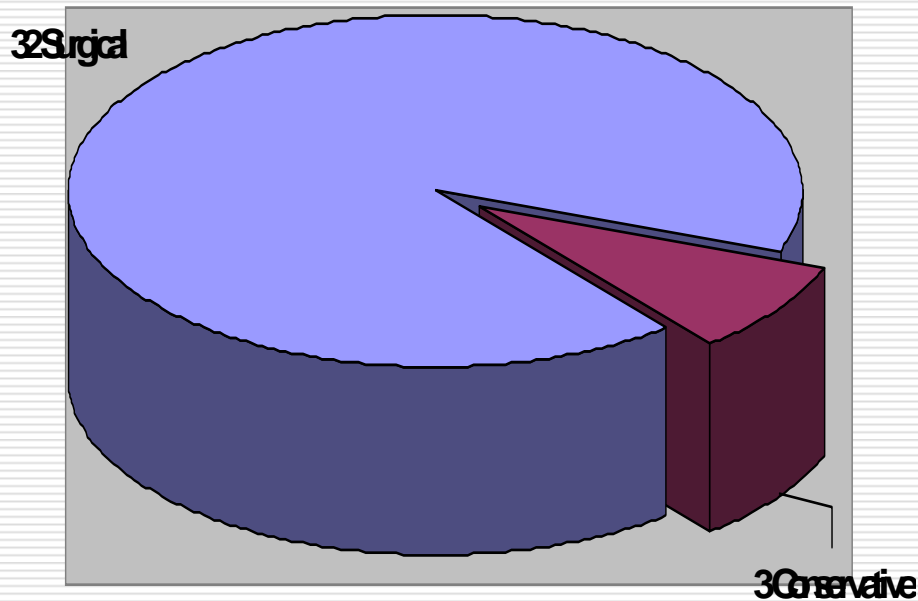
- n=35
- Mean age = 38.7 Years
- M: F =0.52:1
- 13 (37%) patients presented with history of meningitis

AIIMS Experience – Spontaneous CSF rhinorrhoea



Radiological findings (Figure 19)
n-35

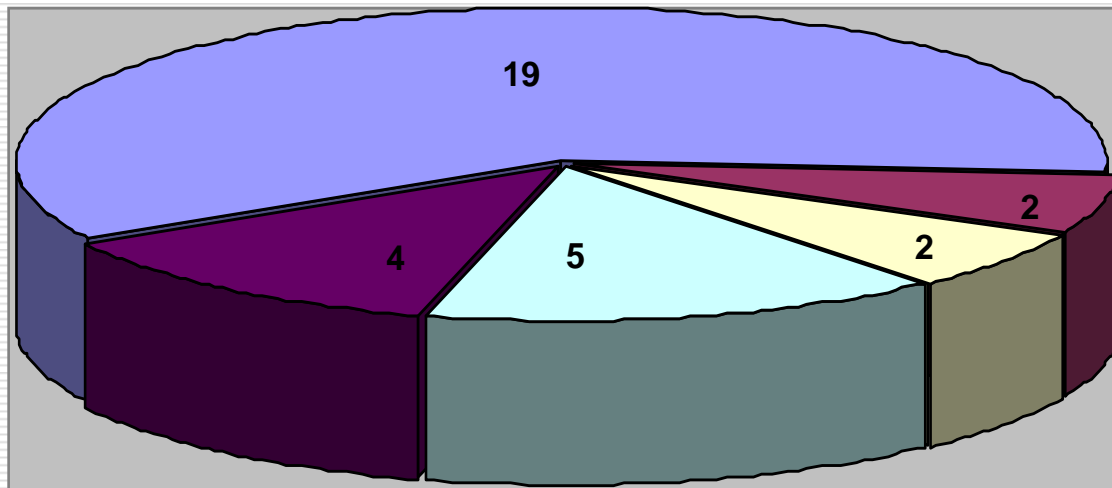
AIIMS Experience – Spontaneous CSF rhinorrhoea



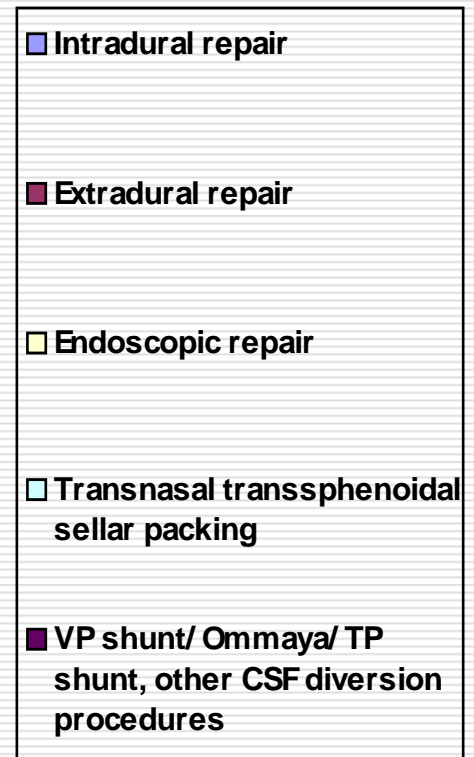
Treatment Modality (Figure 21)

- 3 patients managed conservatively, only 1 require LP drain
- First leaks and patients not having history of recurrent meningitis, responded well to conservative measures alone.

AIIMS Experience – Spontaneous CSF rhinorrhoea



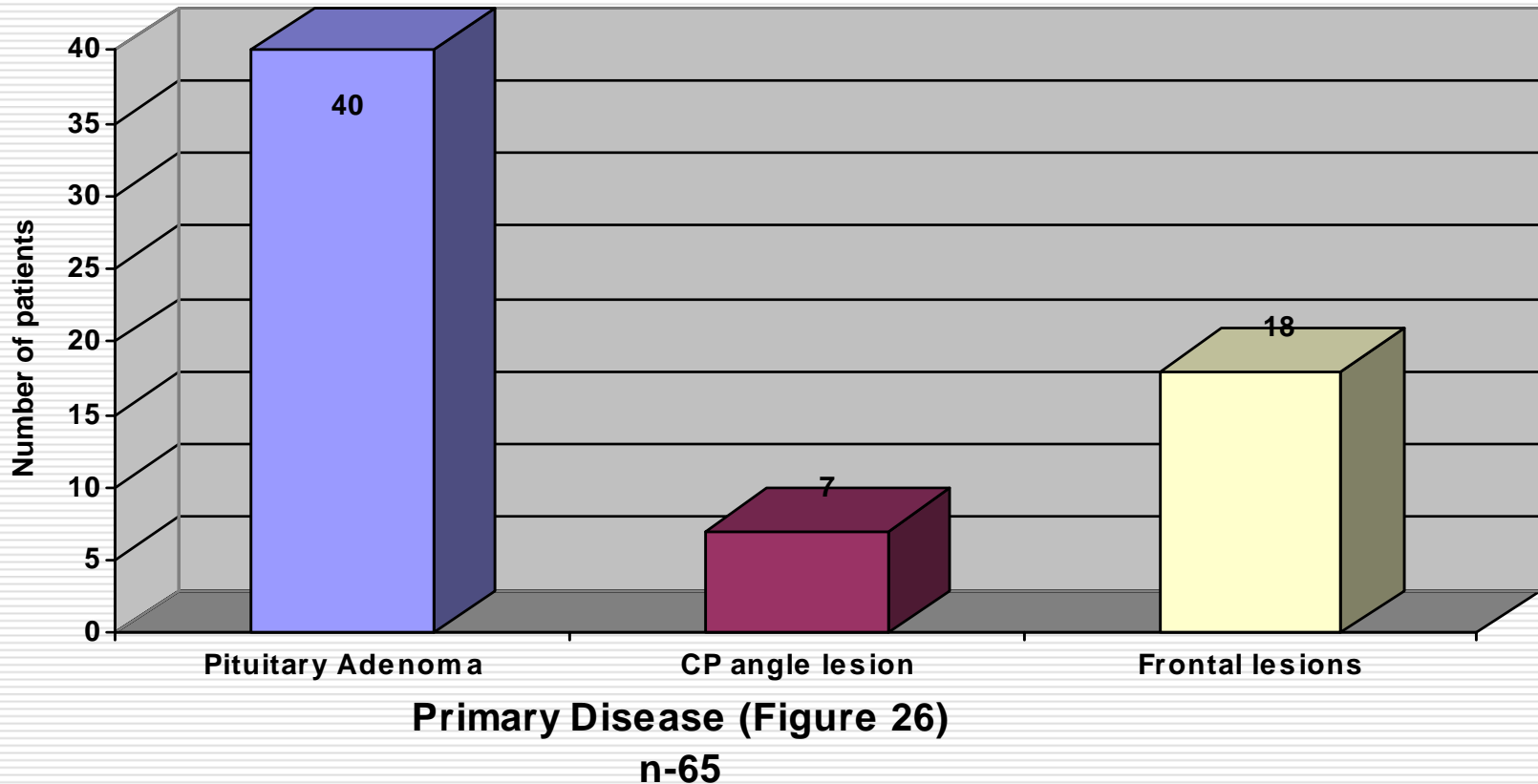
Surgical Management(Figure 21)
n-35



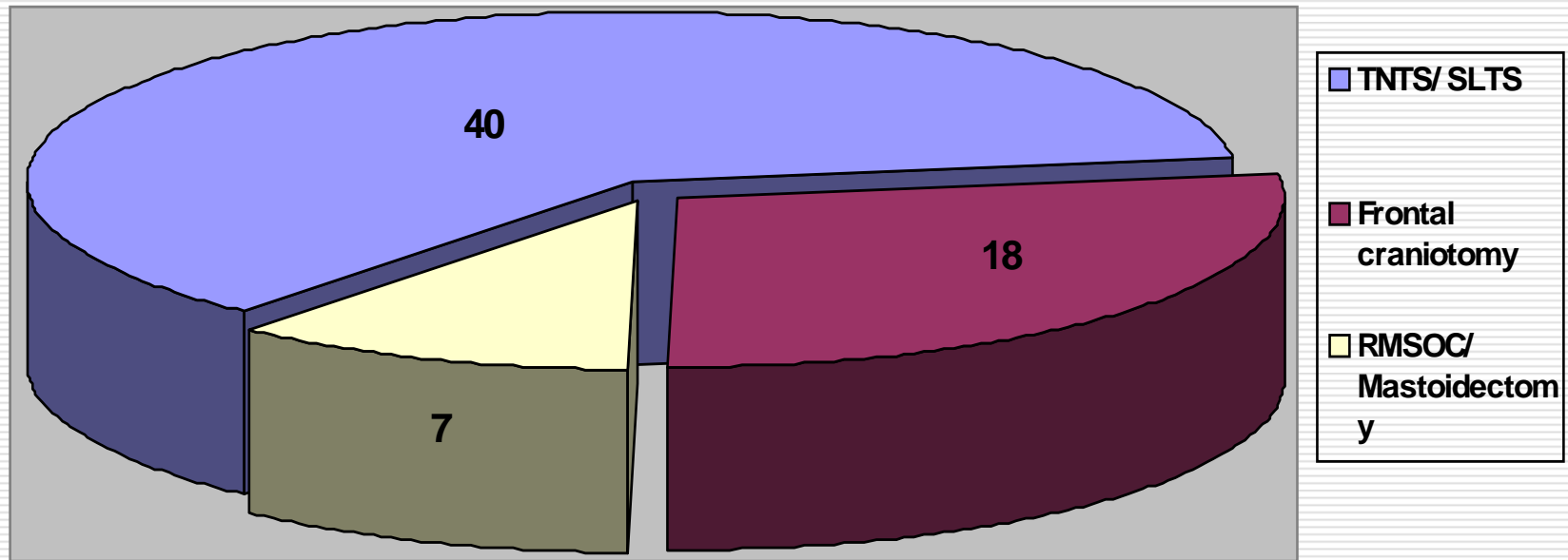
AIIMS Experience – Spontaneous CSF rhinorrhoea

- ❑ **Complications: 4(11.42%)** patients developed postop meningitis
- ❑ **Follow-up and outcome :**
 - Mean follow up -9 m(1 m-2.9 yrs)
 - 29(82.85%) - no further leaks,
 - 2(5.71 %) - recurrence of CSF leak
 - {1/2 required surgery – TP shunt followed by Extradural repair}
 - 1(2.85%) patient died of fulminant post operative meningitis

AIIMS Experience – Post-operative CSF rhinorrhoea

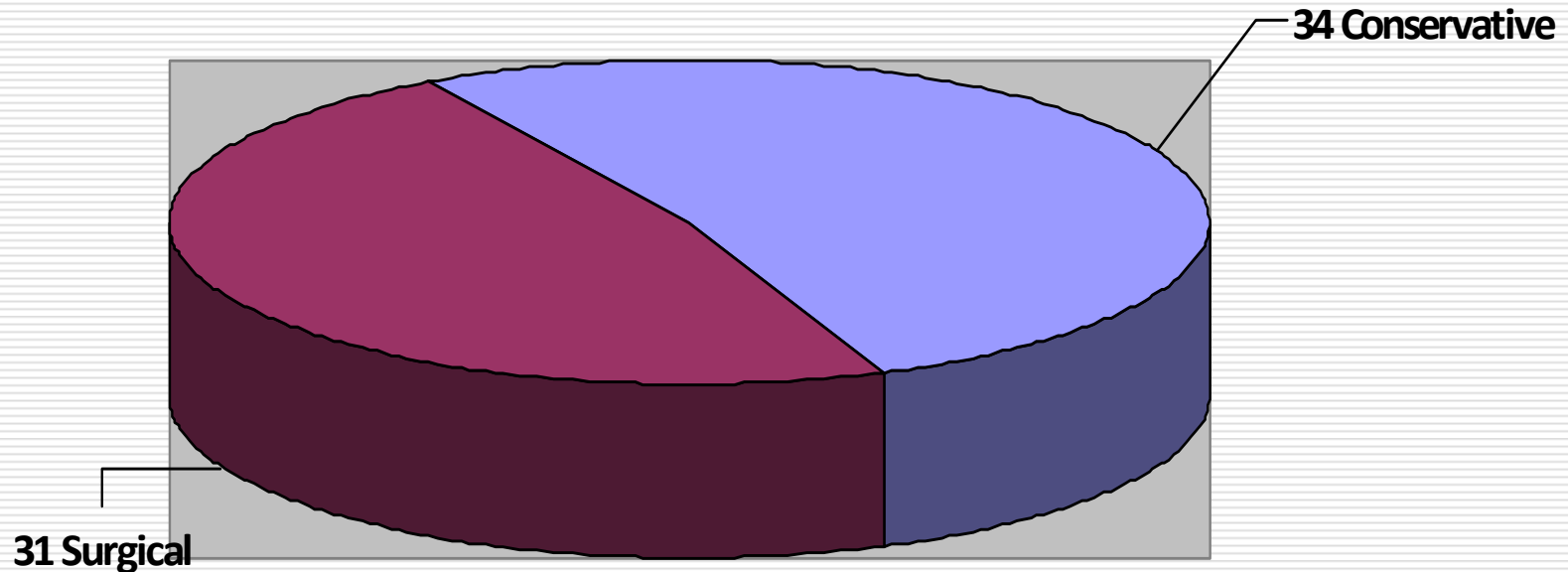


AIIMS Experience – Post-operative CSF rhinorrhoea



Primary Surgery(Figure 27)
n-65

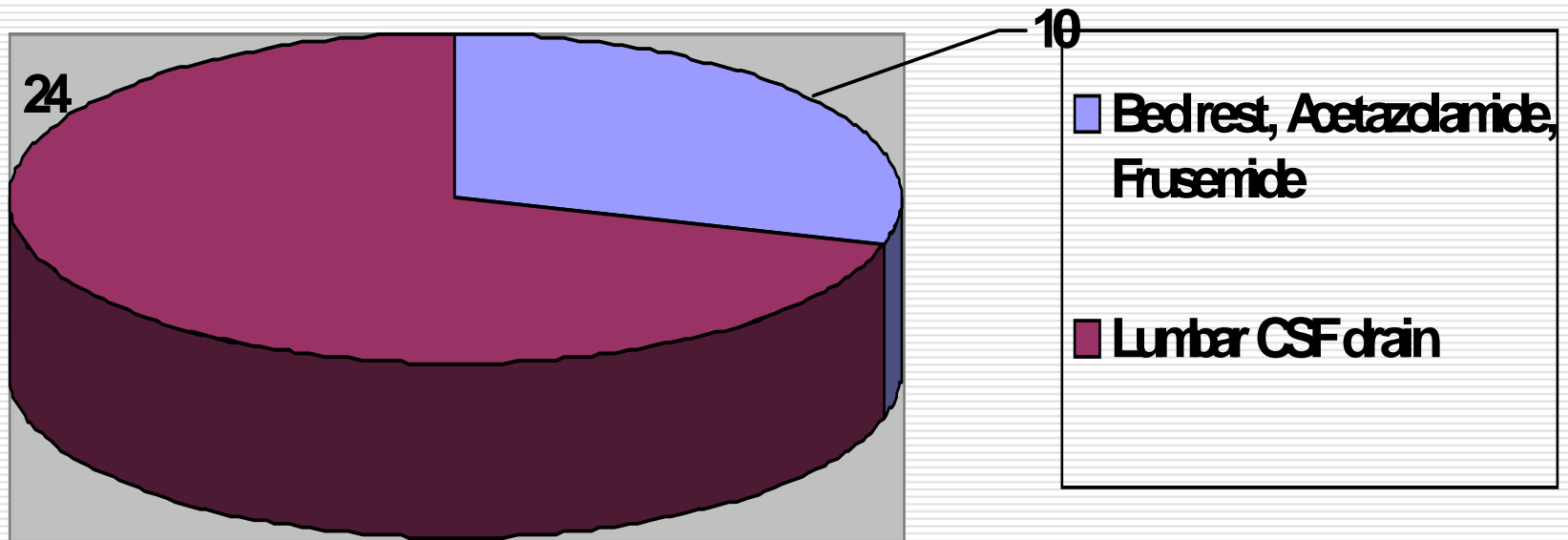
AIIMS Experience – Post-operative CSF rhinorrhoea



Treatment modality (Figure 28)

n-65

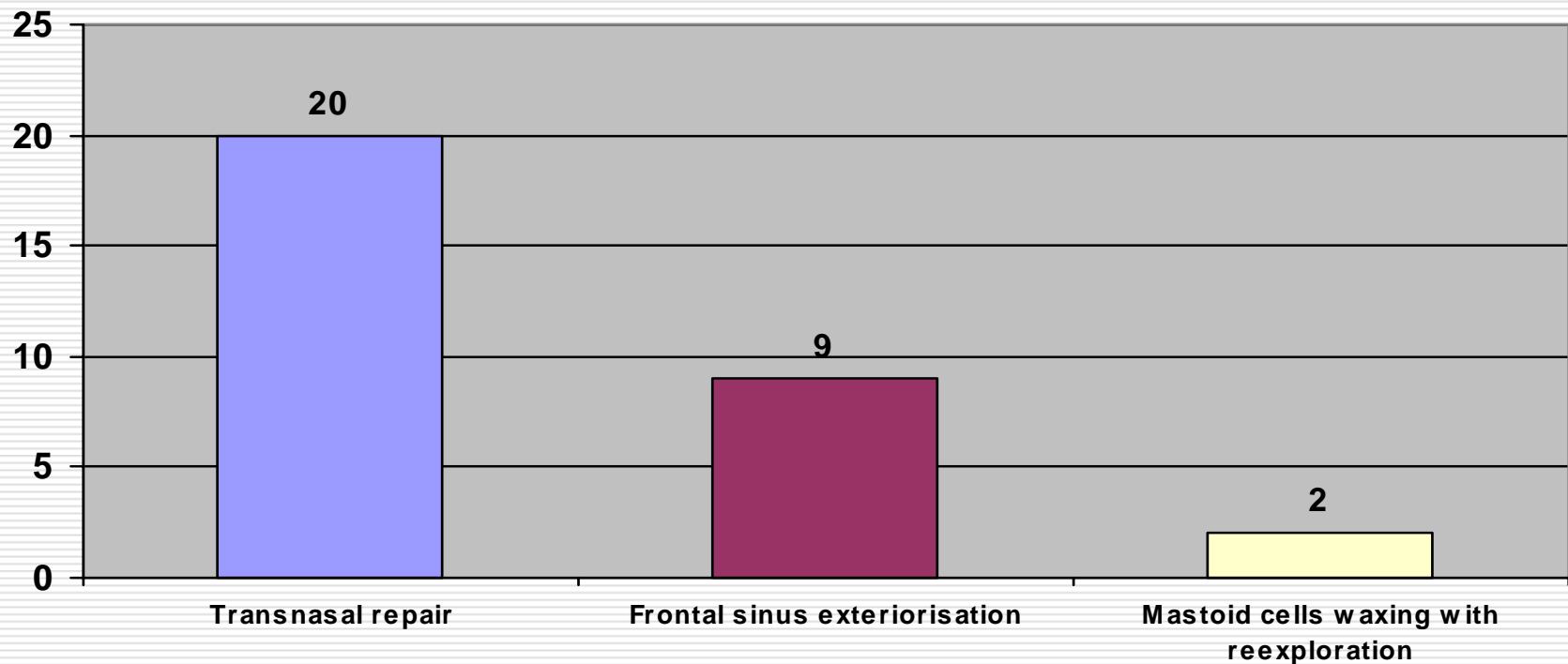
AIIMS Experience – Post-operative CSF rhinorrhoea



Conservative Management (Figure 29)

n-34

AIIMS Experience – Post-operative CSF rhinorrhoea



Surgical Management (Figure30)
n-31

AIIMS Experience – Post-operative CSF rhinorrhoea

- **Complications:** Nine (13.8%) patients developed complications.

7(10.76%)-Postop meningitis, 2(3%)- Septicemia

- **Follow-up and outcome :**

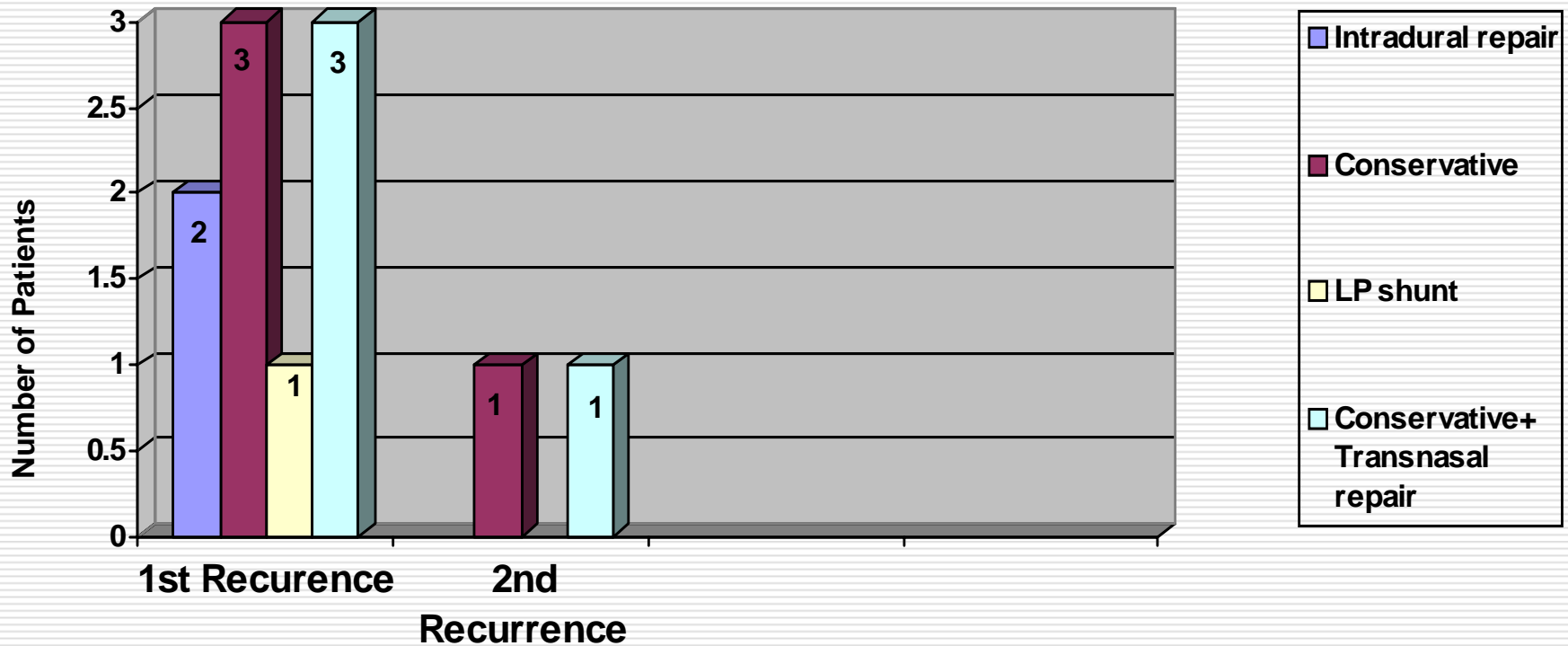
Mean follow up -10 m(1 m-4.4 yrs)

46 (70.8%) - no further leaks,

9(13.8 %) - recurrence of CSF leak

4(6.1 %) patients died in post op. period

AIIMS Experience – Post-operative CSF rhinorrhoea



Management of Recurrence (Figure 32)

CSF rhinorrhoea – The Way Ahead

- ❑ Improved flexible endoscopy
- ❑ Availability of biological glue
- ❑ Newer non-invasive 3-D imaging techniques for fistula localization
- ❑ Minimally invasive approach

Take Home message

- ❑ CSF rhinorrhoea- potentially life threatening owing to risk of meningitis
- ❑ MC cause- trauma with Basilar skull #, though post-operative leaks are also on the rise
- ❑ MC site – Cribriform plate of ethmoid
- ❑ Diagnosis by a variety of Clinical & radiological techniques, though MR cisternography with heavily T2W and 3D CISS sequences being the modality of choice
- ❑ Conservative and surgical management depending on the cause, site and duration of CSF leak
- ❑ Variety of Intracranial/ Extracranial , open/ endoscopic approaches available
- ❑ Future trend is towards minimally invasive endoscopic approaches

Thank You

Saturday, September
20, 2008